

Ecografía intestinal: Novedades del pasado

Dr. Gonzalo Cárdenas Loguercio
Médico Radiólogo
Unidad de Imágenes de abdomen y pelvis
Hospital Clínico de la Universidad de Chile

Ecografía intestinal: Novedades del futuro

Dr. Gonzalo Cárdenas Loguercio
Médico Radiólogo
Unidad de Imágenes de abdomen y pelvis
Hospital Clínico de la Universidad de Chile

Ecografía intestinal

PATOLOGIA AGUDA

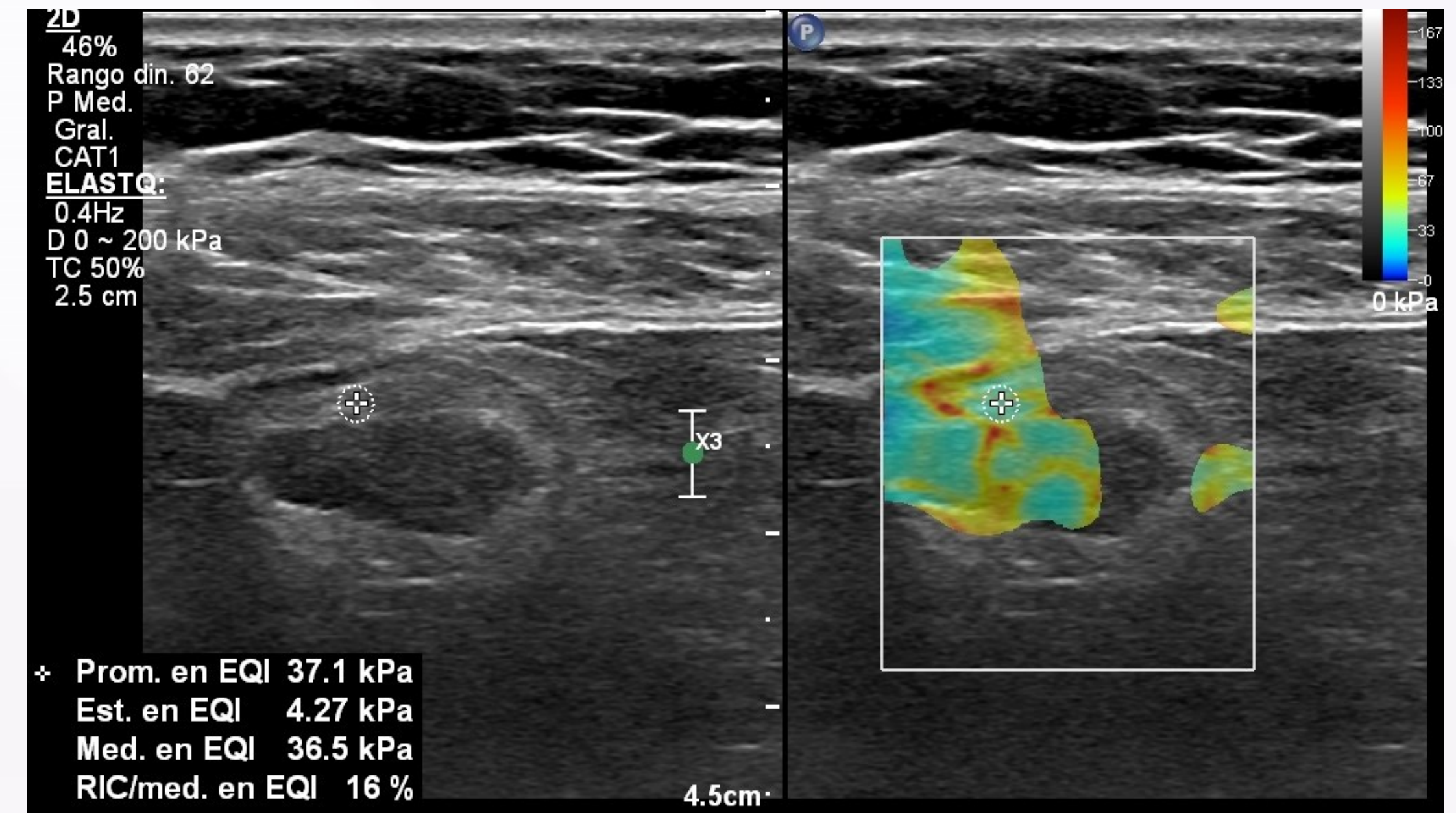


Dolor abdominal
agudo
Apendicitis
Diverticulitis
Colitis
Ileitis
Apendagitis

CONTROL EII

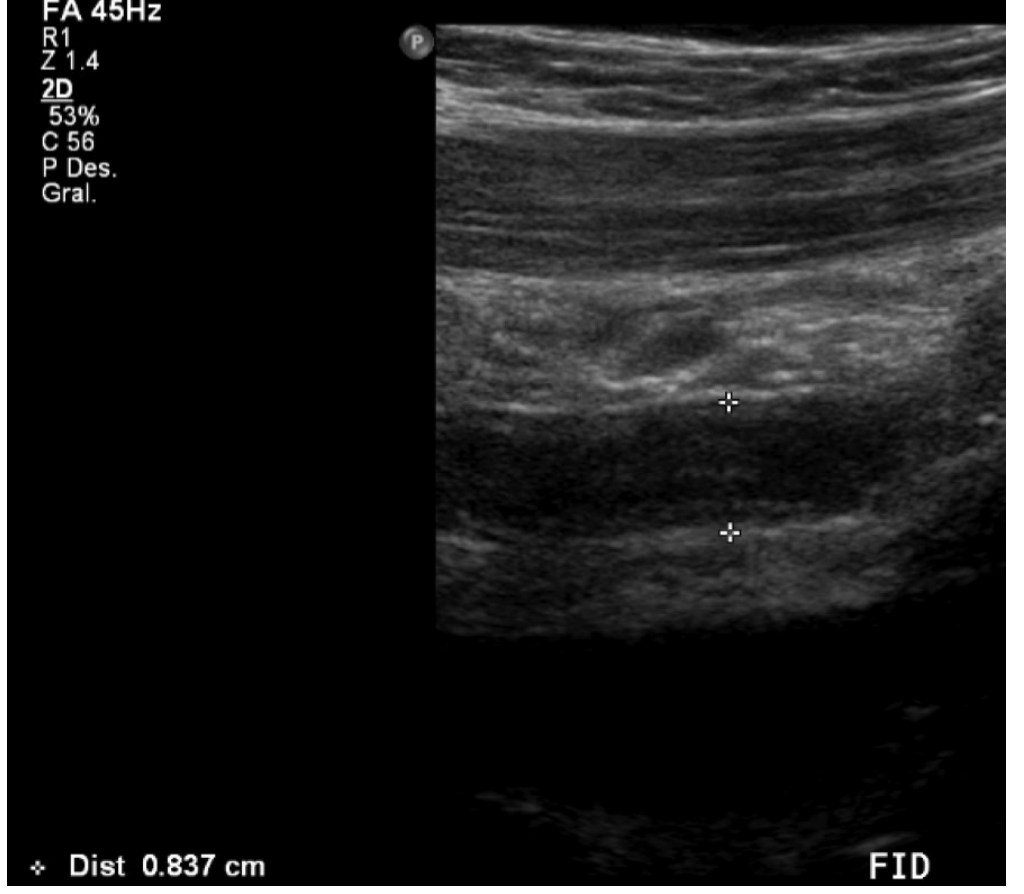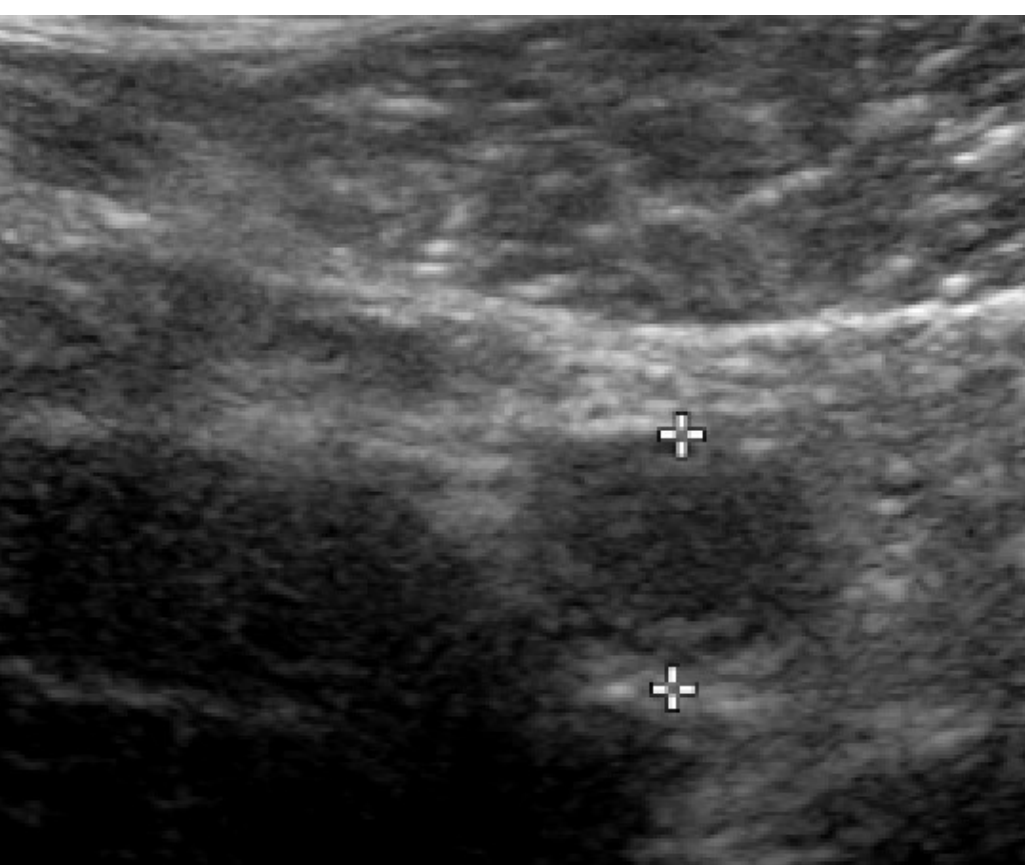
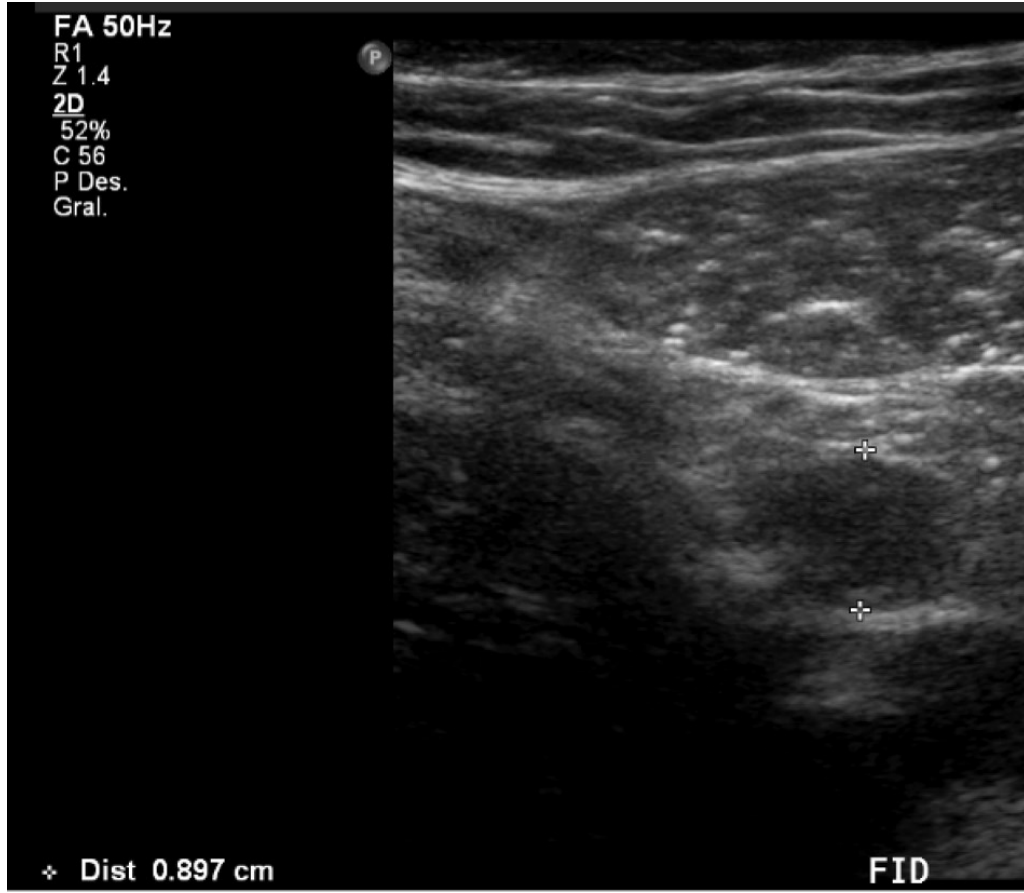
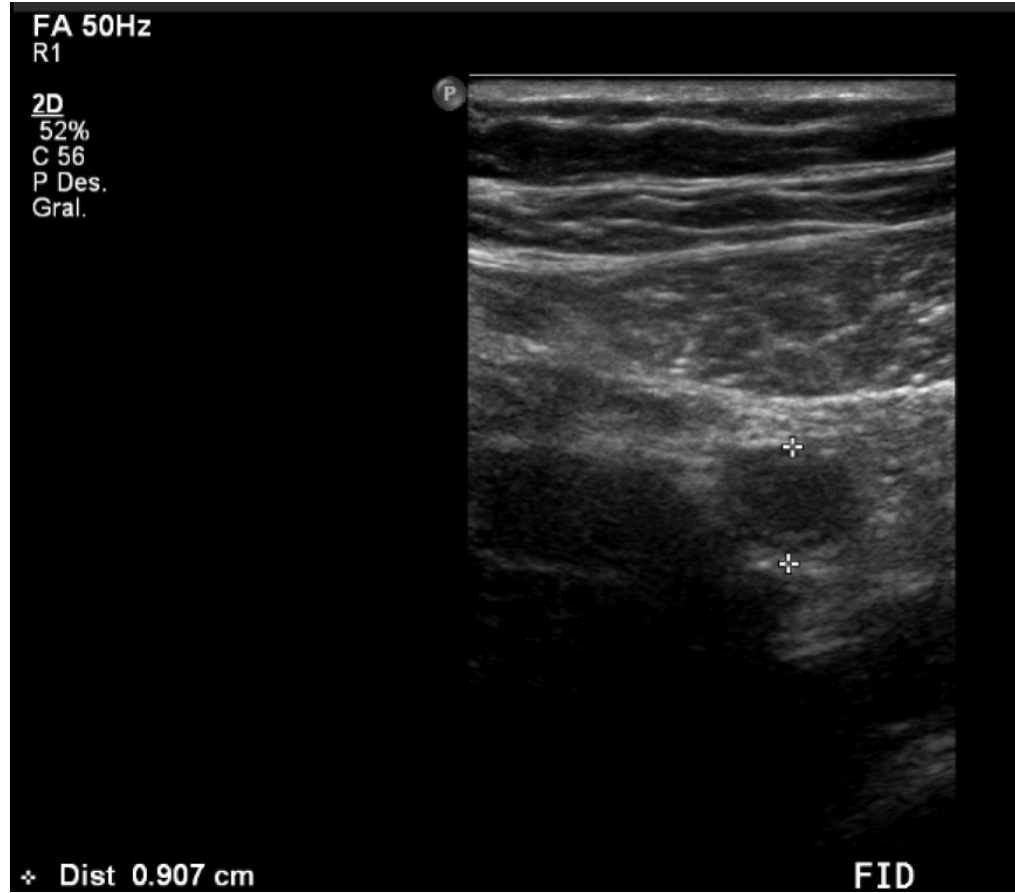


Enfermedad de
Crohn
Colitis Ulcerosa
Otras enteritis
Neoplasia?



Ecografía intestinal: Patología Aguda

Apendicitis Aguda



Radiology

Caroline Keyzer, MD
 Marc Zalcman, MD
 Viviane De Maertelaer, PhD
 Emmanuel Coppens, MD
 Maria-Antonietta Bali, MD
 Pierre Alain Gevenois, MD, PhD
 Daniel Van Gansbeke, MD

Comparison of US and Unenhanced Multi-Detector Row CT in Patients Suspected of Having Acute Appendicitis¹

ECOGRAFIA

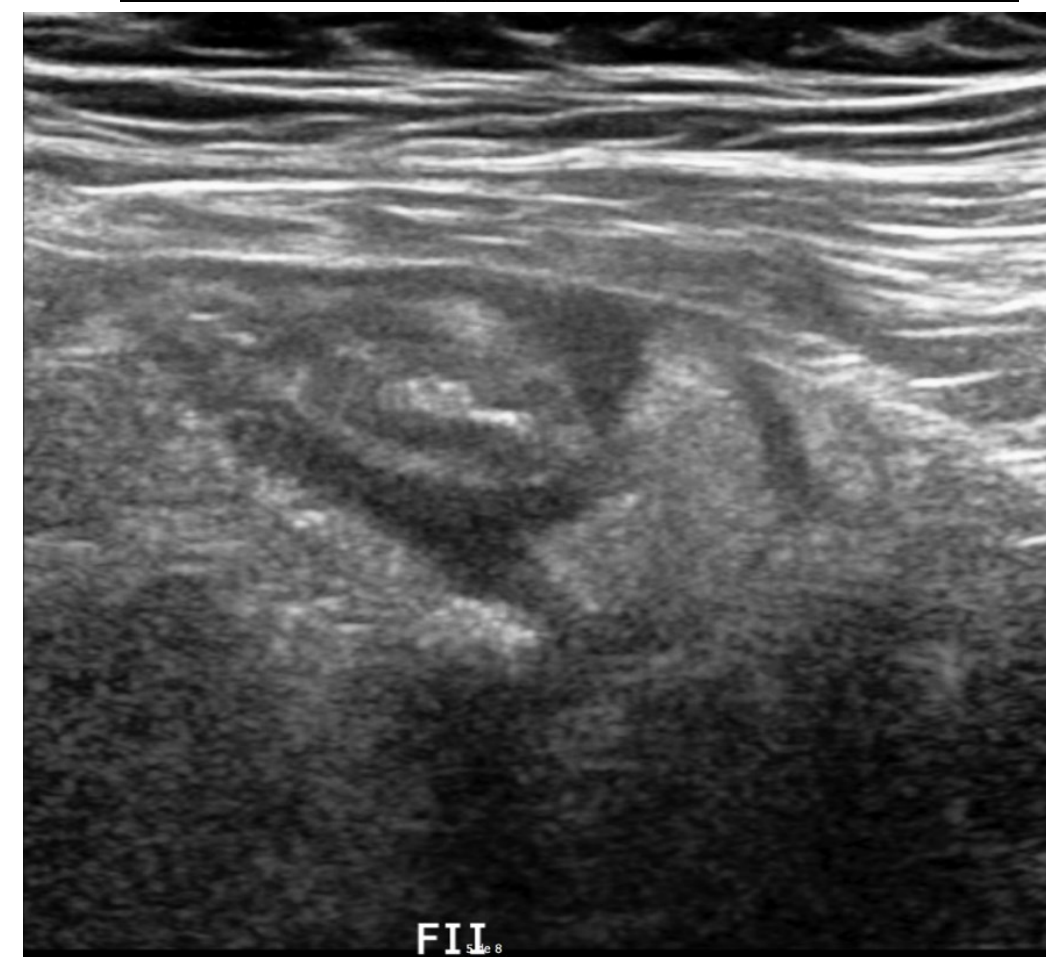
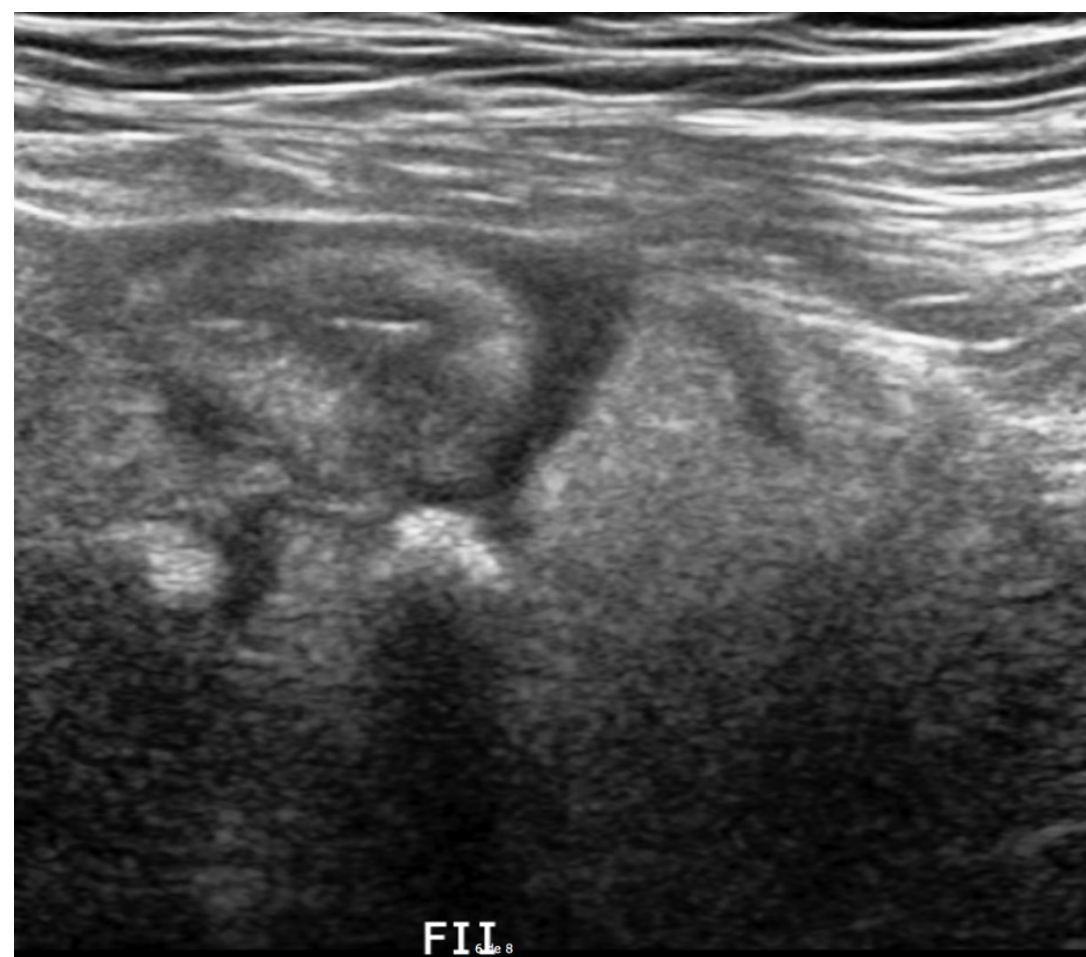
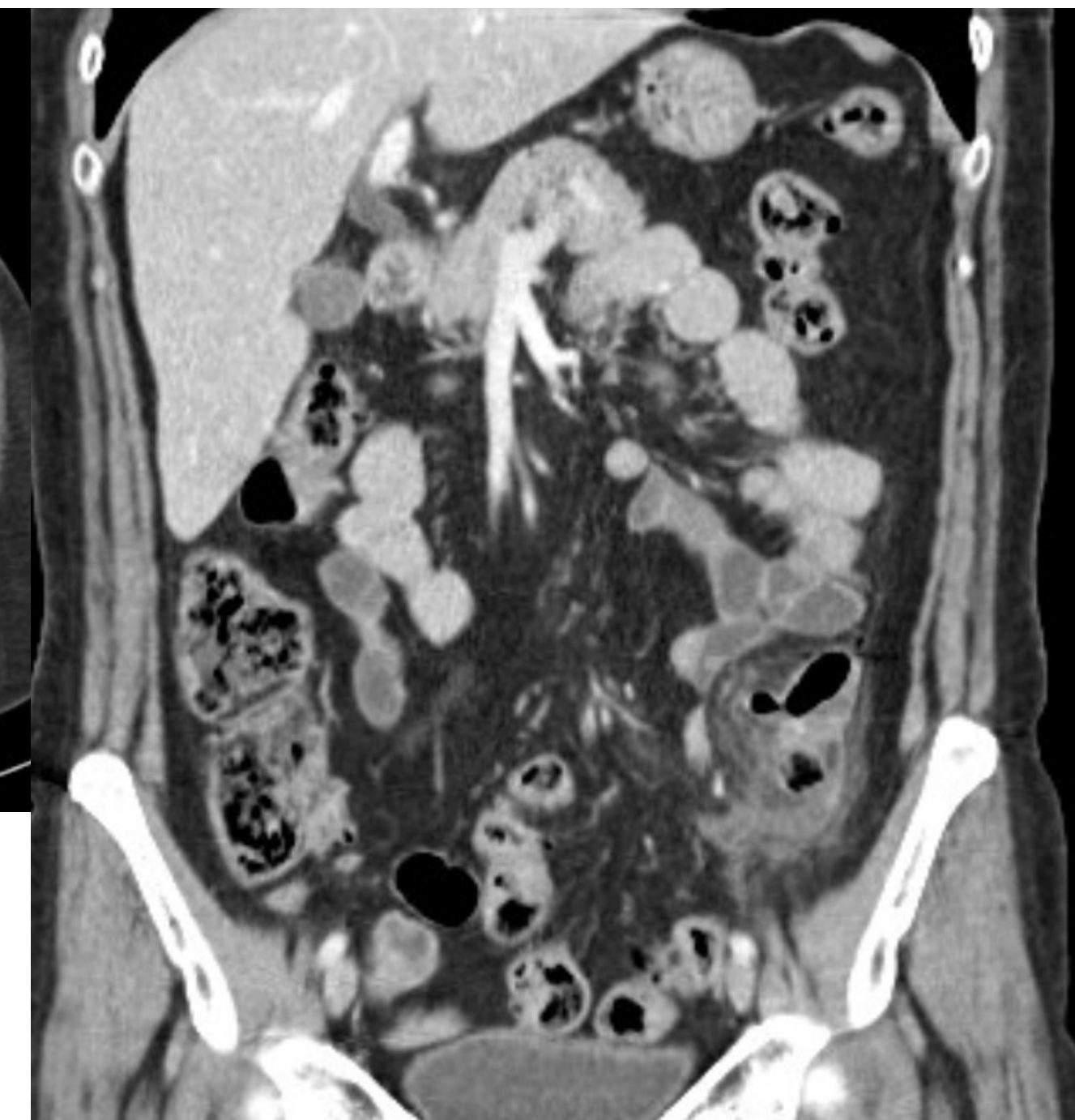
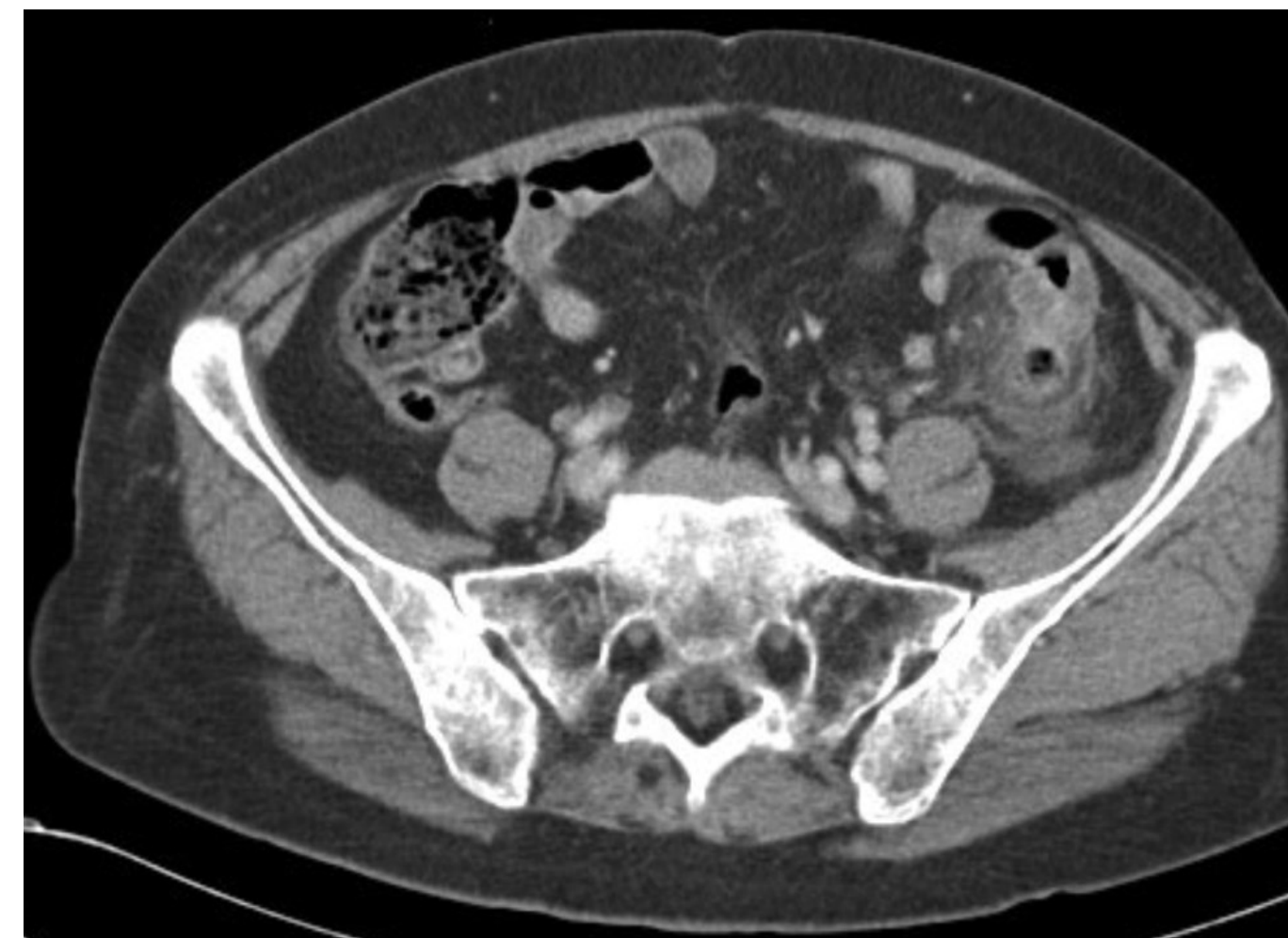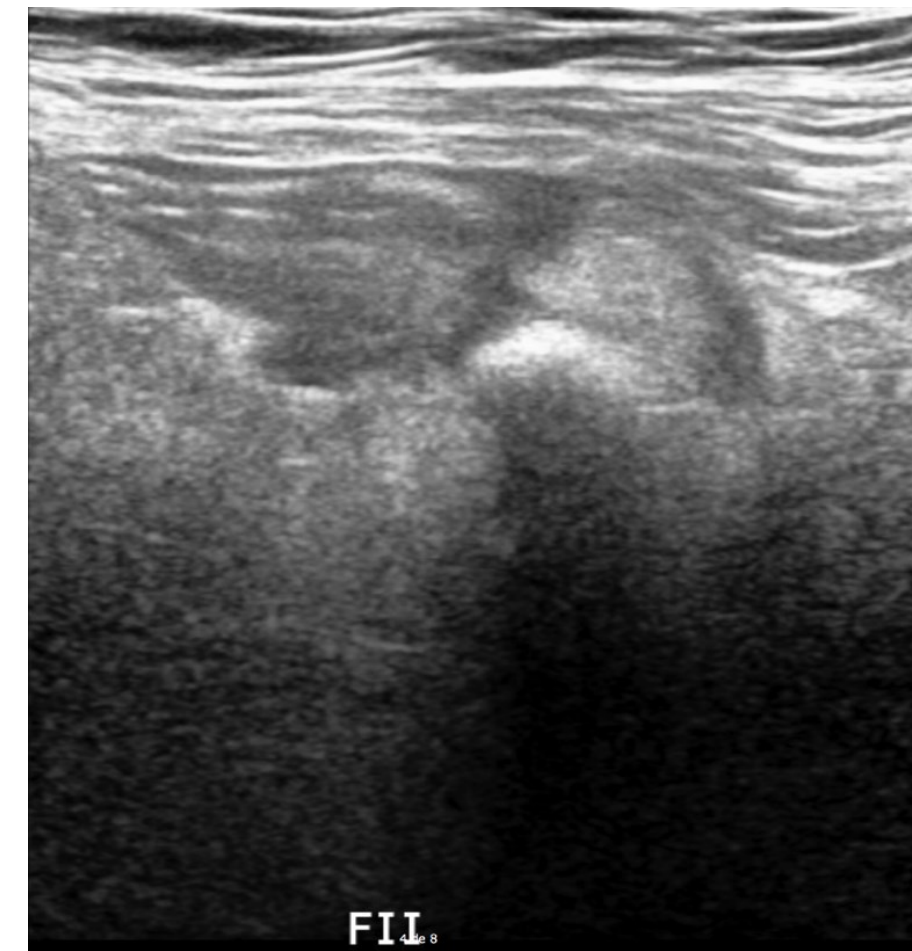
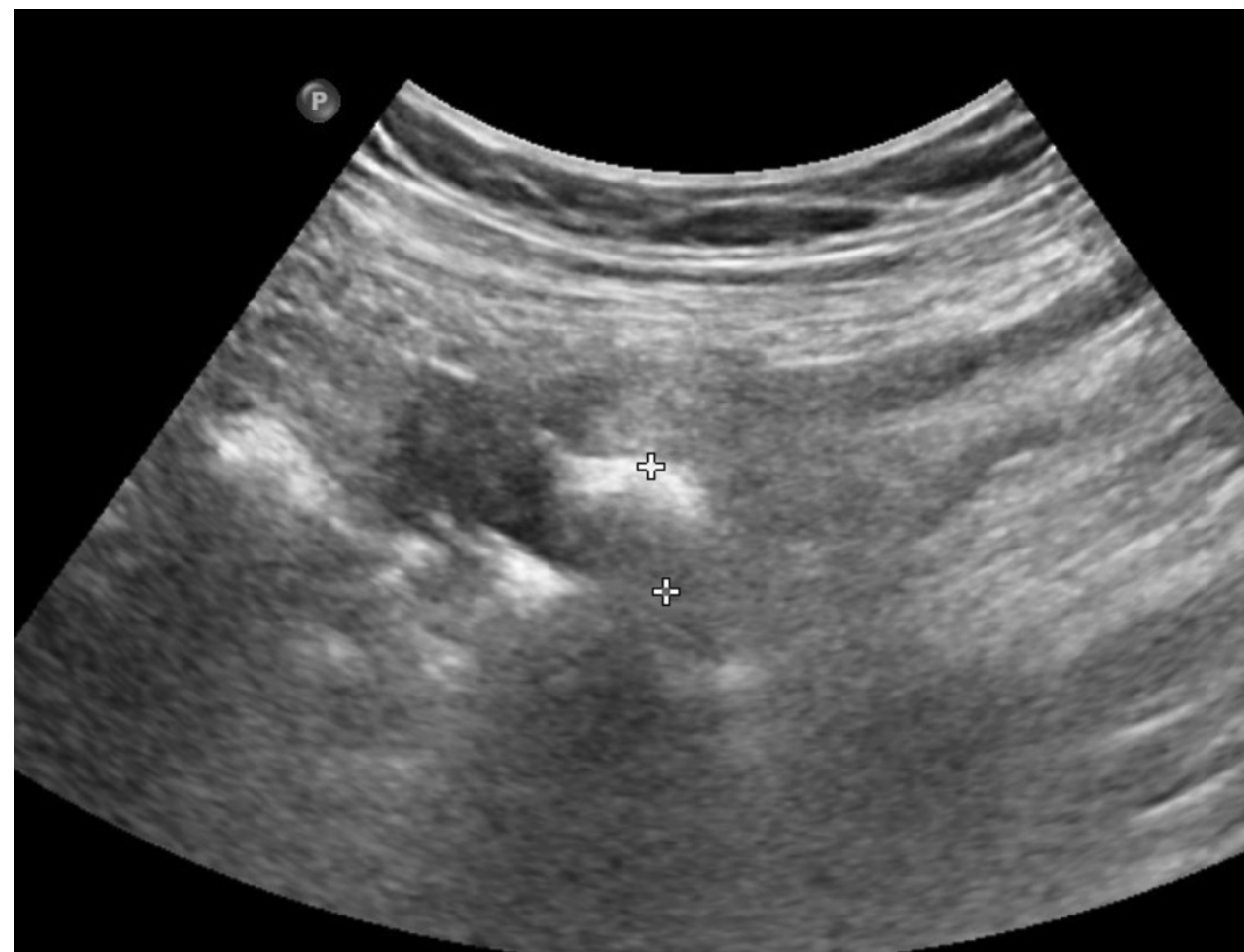- Sensibilidad 76%-90%
- Especificidad 86-100%
- VPP 71-95%
- VPN 75-98%

TOMOGRAFIA COMPUTADA

- Sensibilidad >95%
- Especificidad

Ecografía intestinal: Patología Aguda

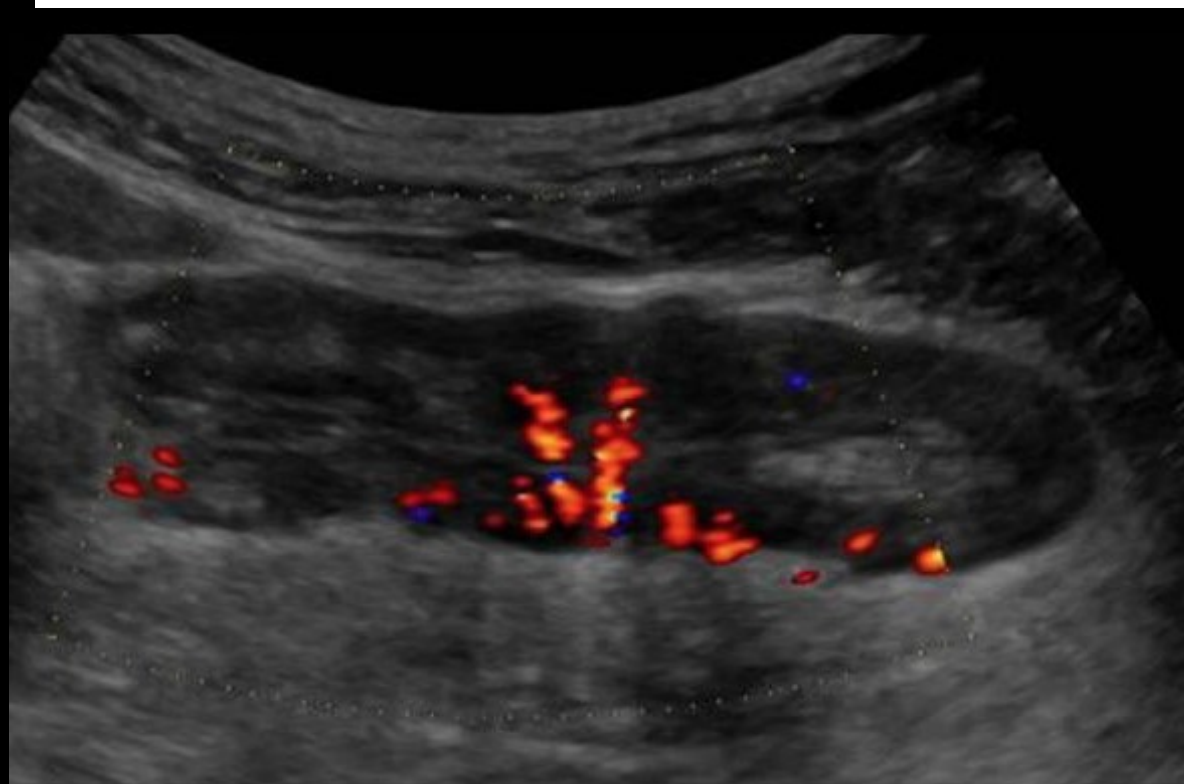
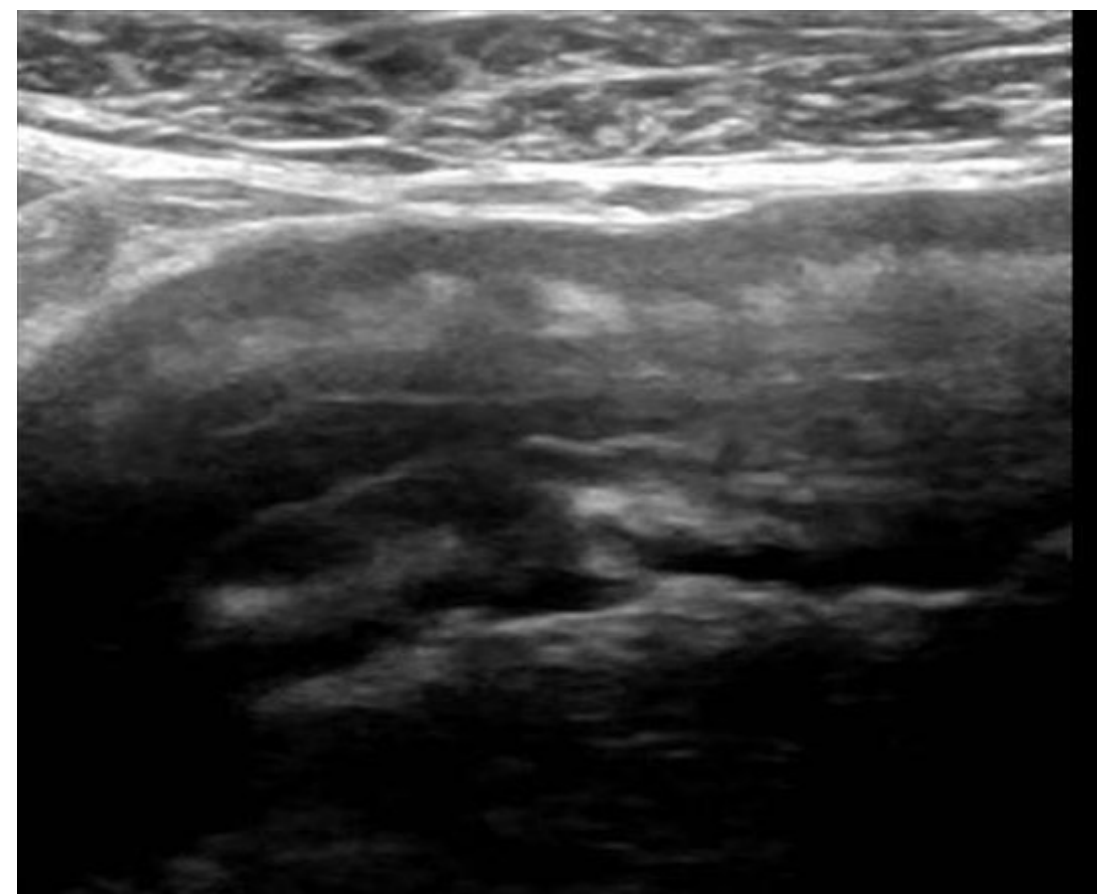
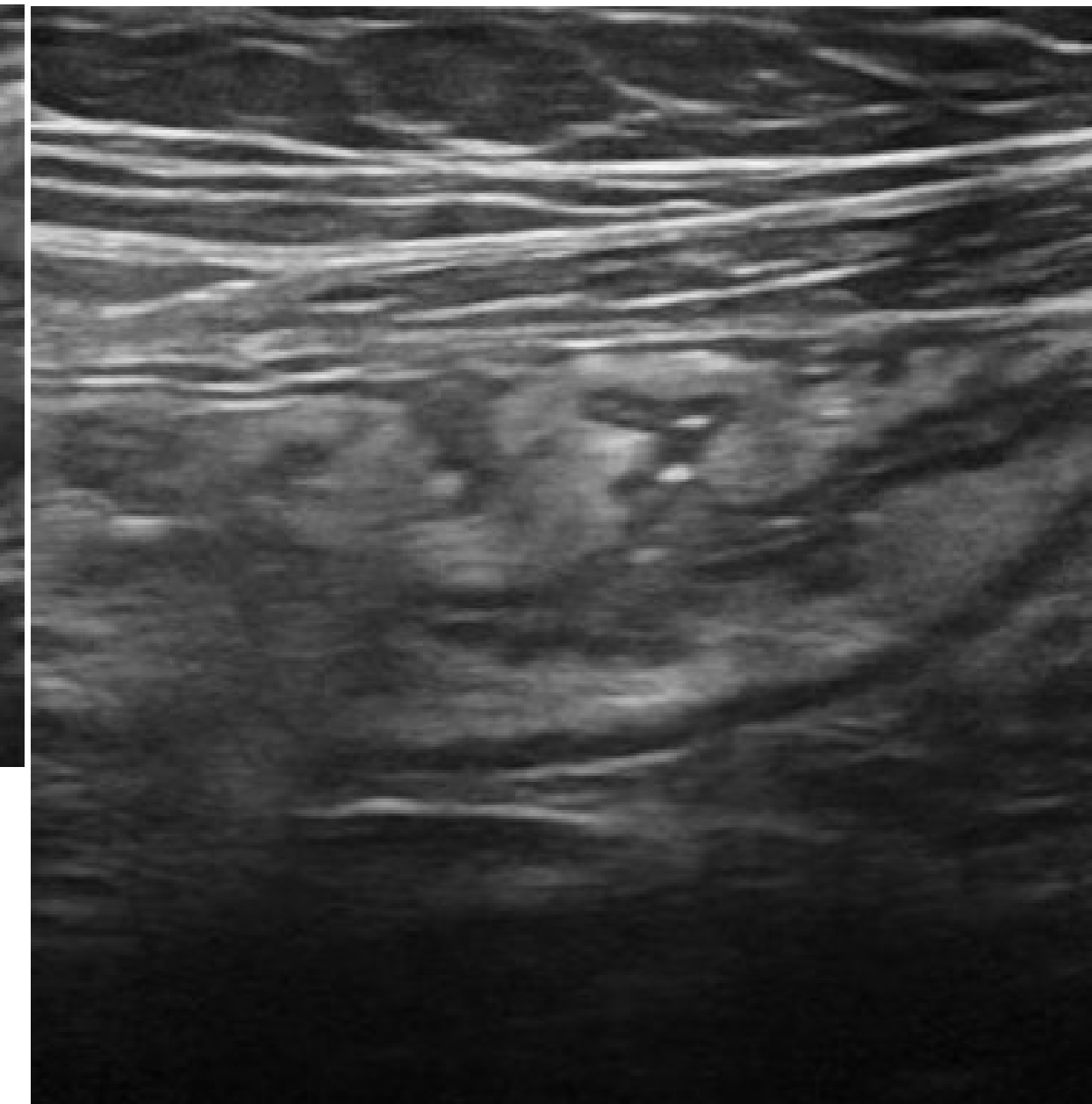
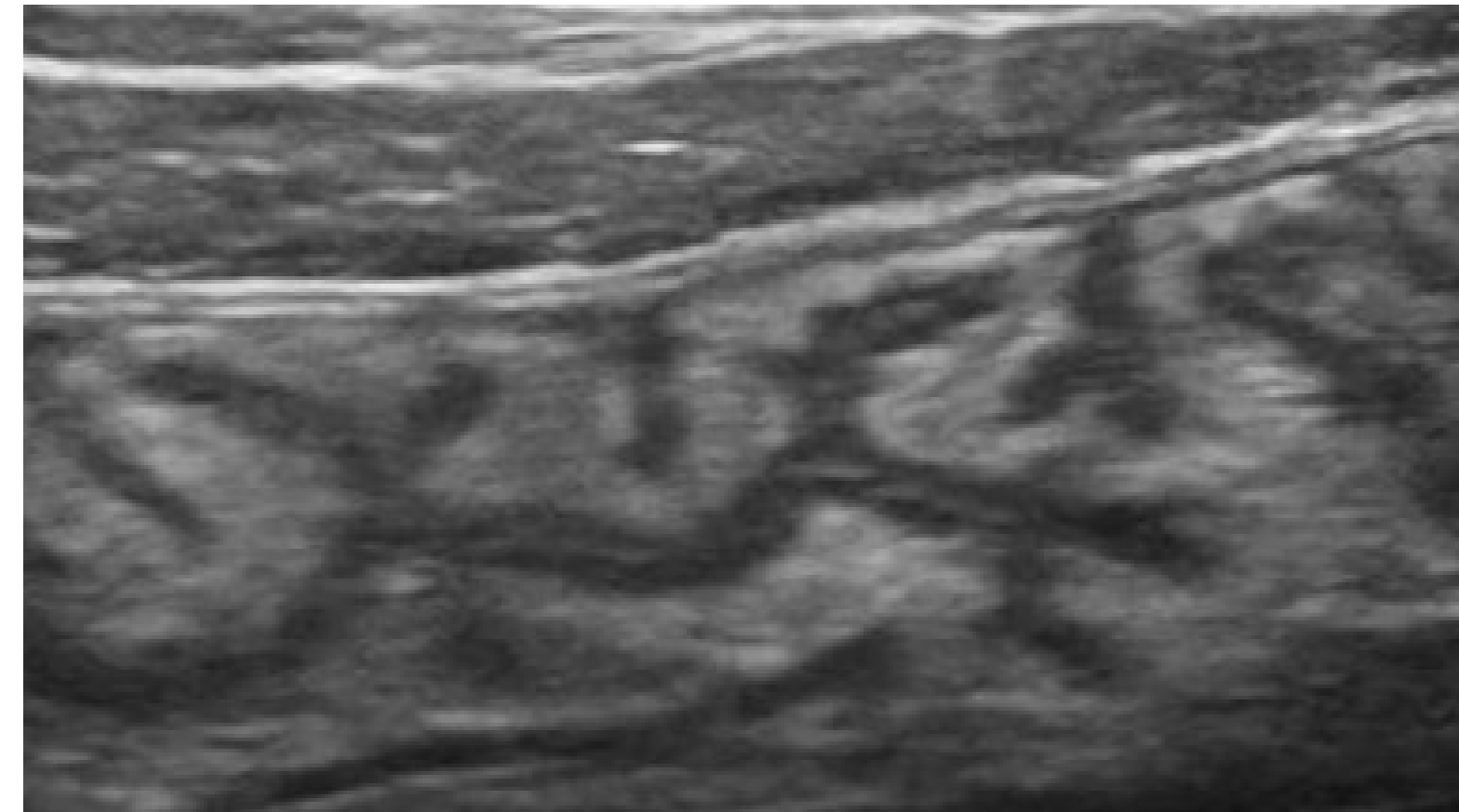
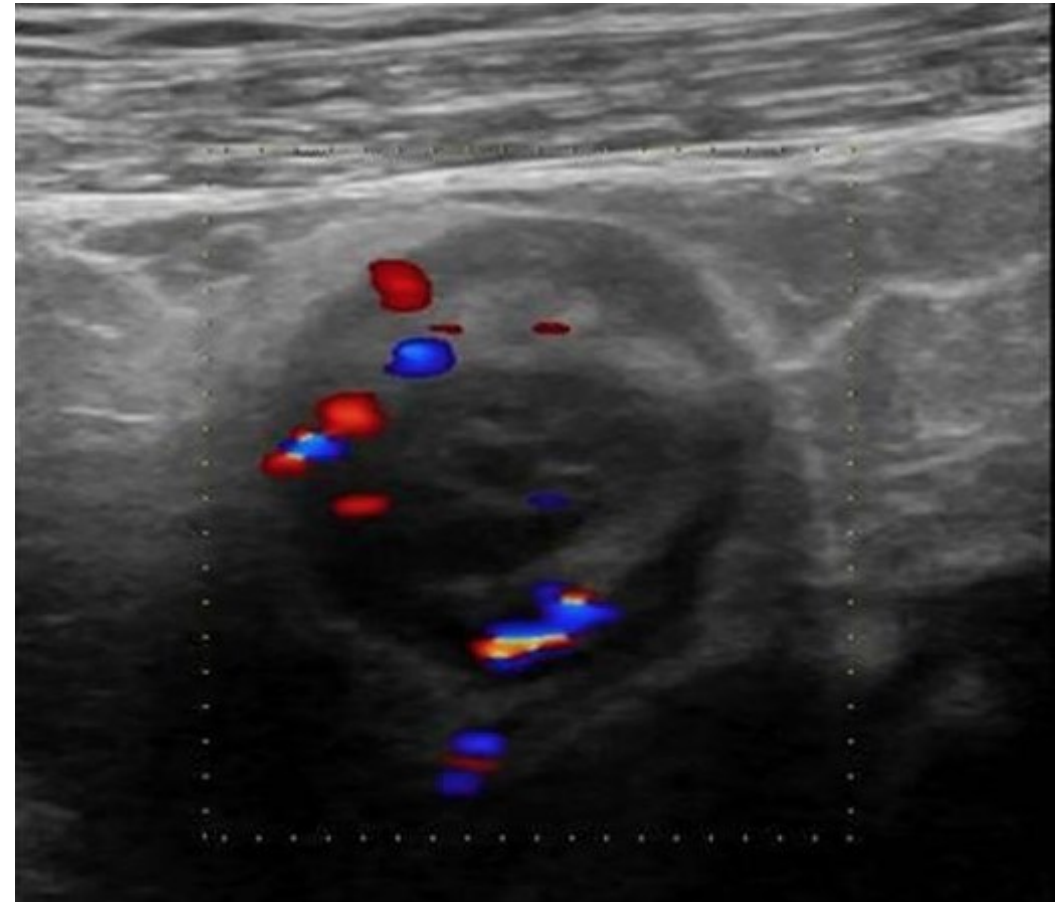
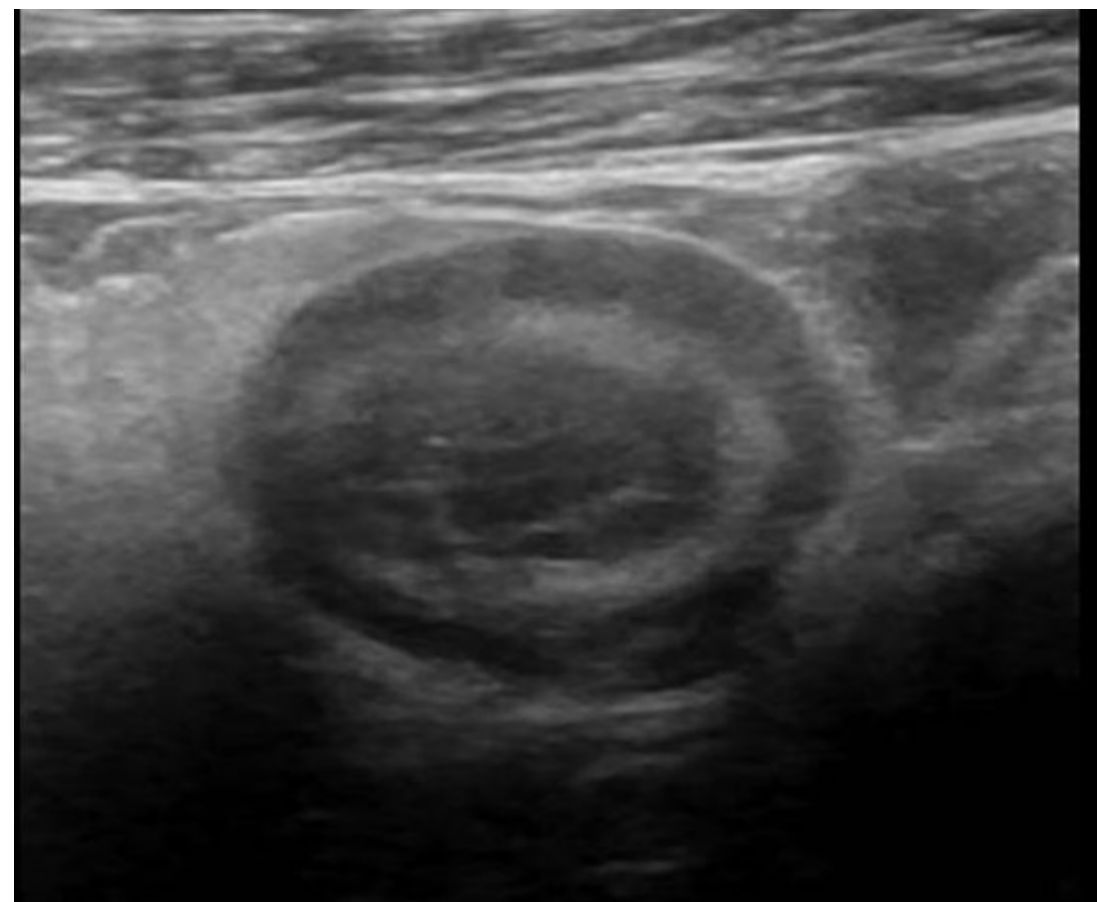
DIVERTICULITIS



Ecografía intestinal: Patología Aguda

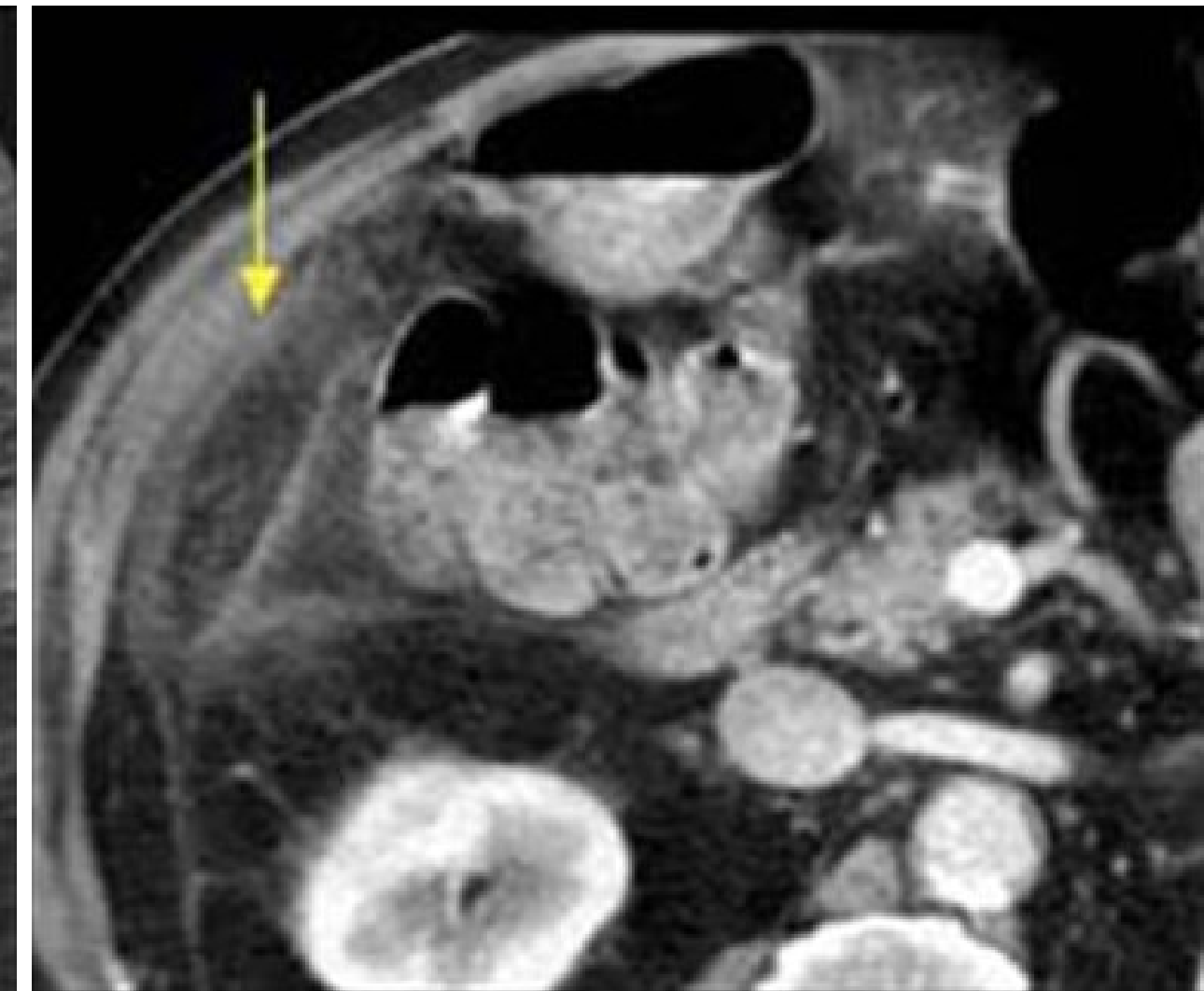
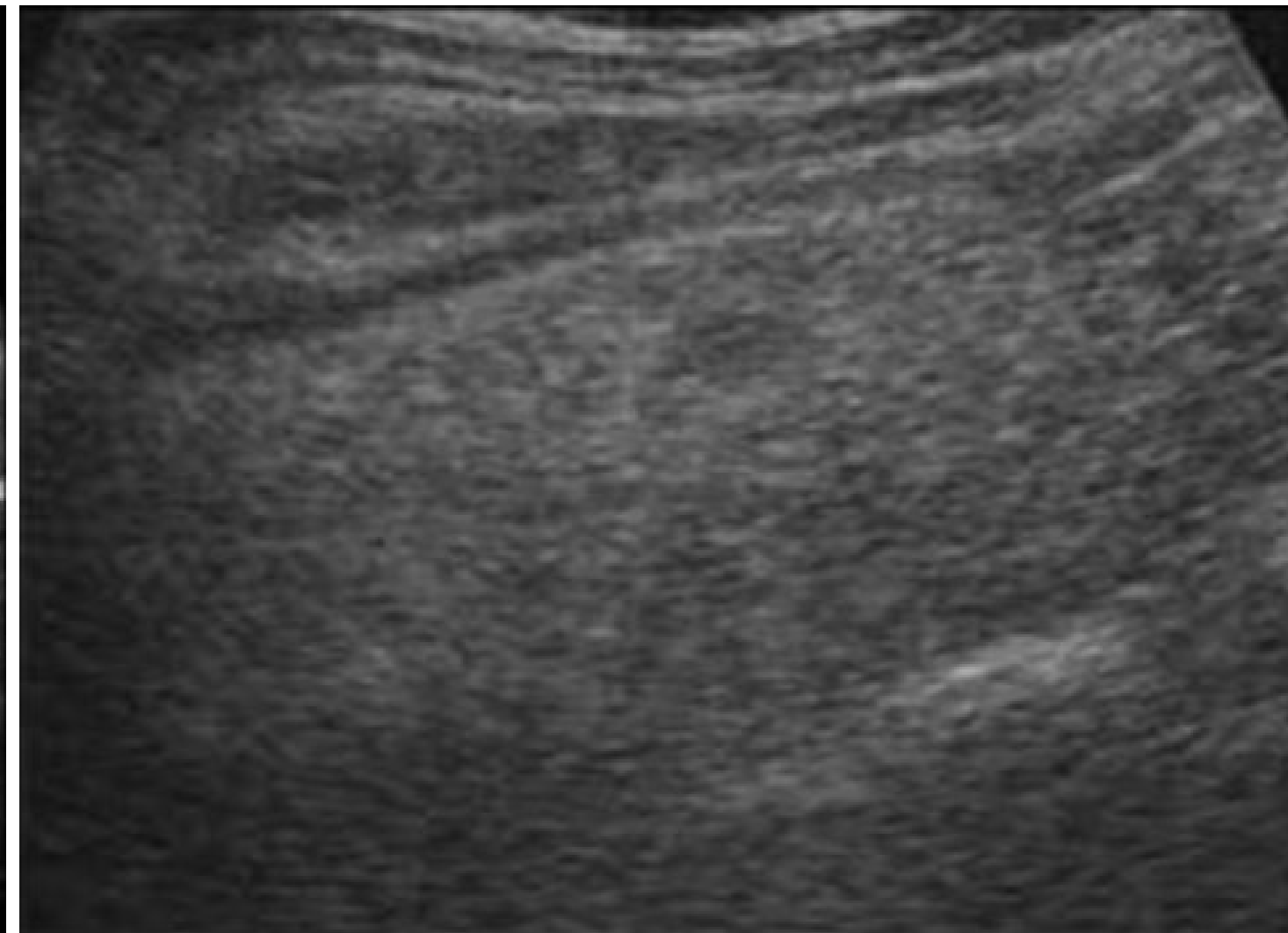
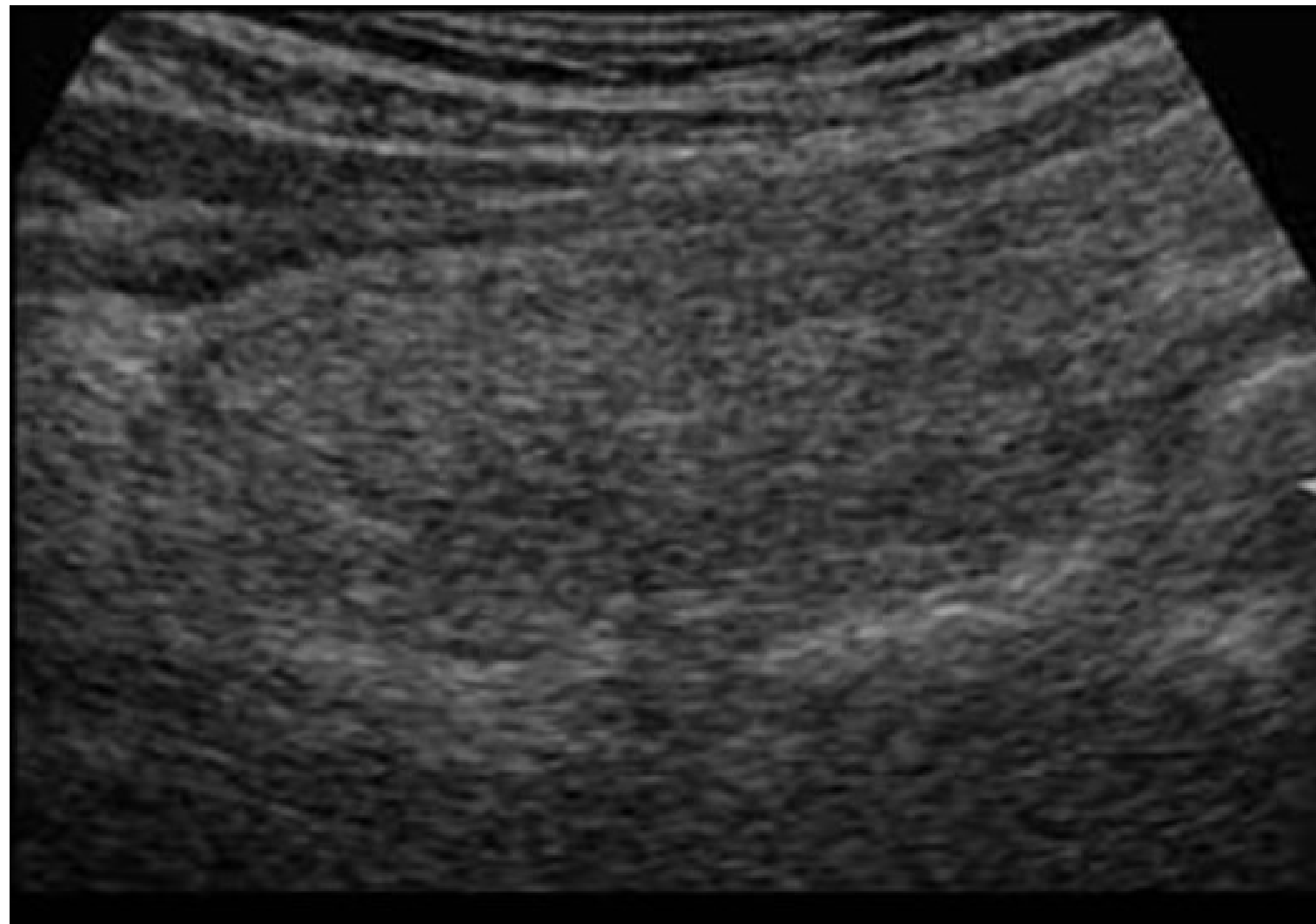
Ileitis

Colitis



Ecografía intestinal: Patología Aguda

Apendagitis



Ecografía intestinal: Enfermedad Inflamatoria Intestinal

Colonoscopia

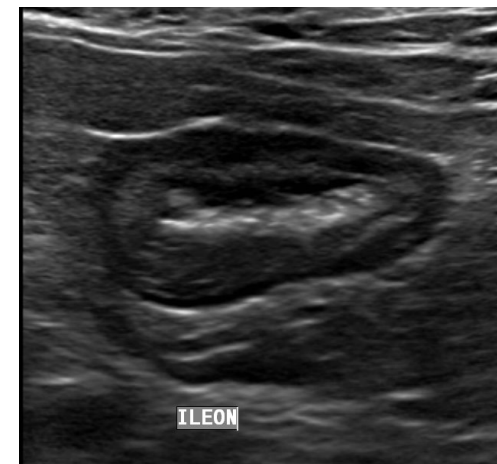

Valor
Acceso
Reproductibilidad
Preparación

Imágenes

ECOGRAFIA

- Control de tratamiento estenosis
- Complicaciones extramurales



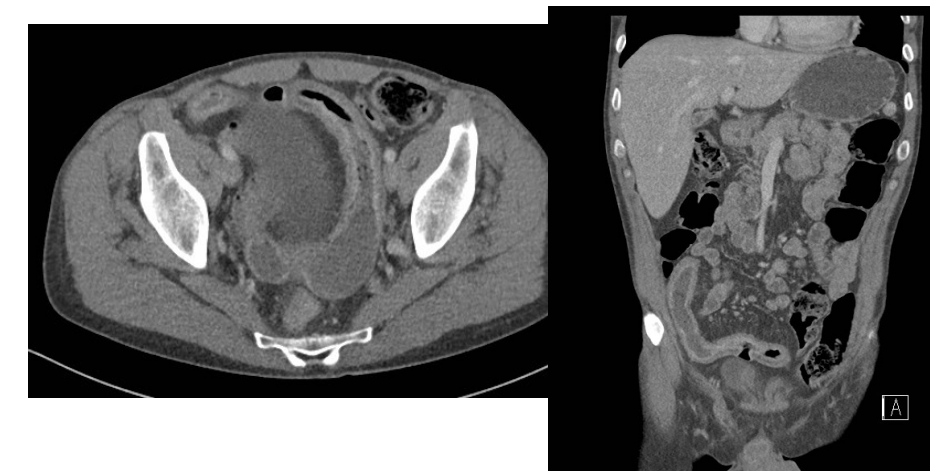
TOMOGRAFIA COMPUTADA

TC convencional

ENTEROTC

- Diagnóstico
- Complicaciones

- Diagnóstico
- Complicaciones
- Evaluación de actividad?



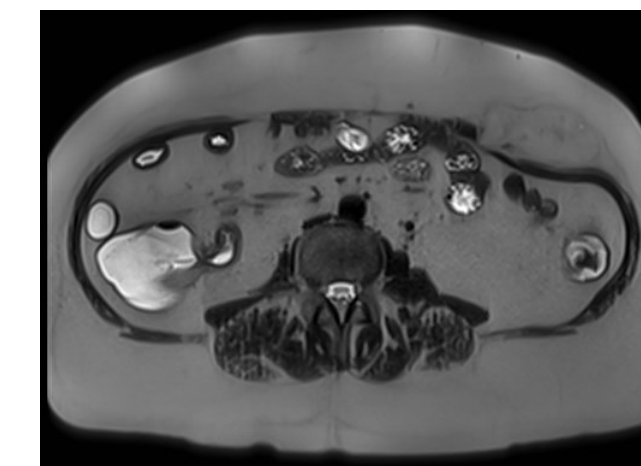
RESONANCIA MAGNETICA

RM convencional

EnteroRM

- Complicaciones
- Evaluación de patología pelviana.

- Complicaciones
- Evaluación de actividad



Ecografía intestinal: Enfermedad Inflamatoria Intestinal

Ecografía intestinal

Journal of Crohn's and Colitis, 2019, 144–164K
 doi:10.1093/ecco-jcc/ijy113
 Advance Access publication August 23, 2018
 ECCO Guideline/Consensus Paper



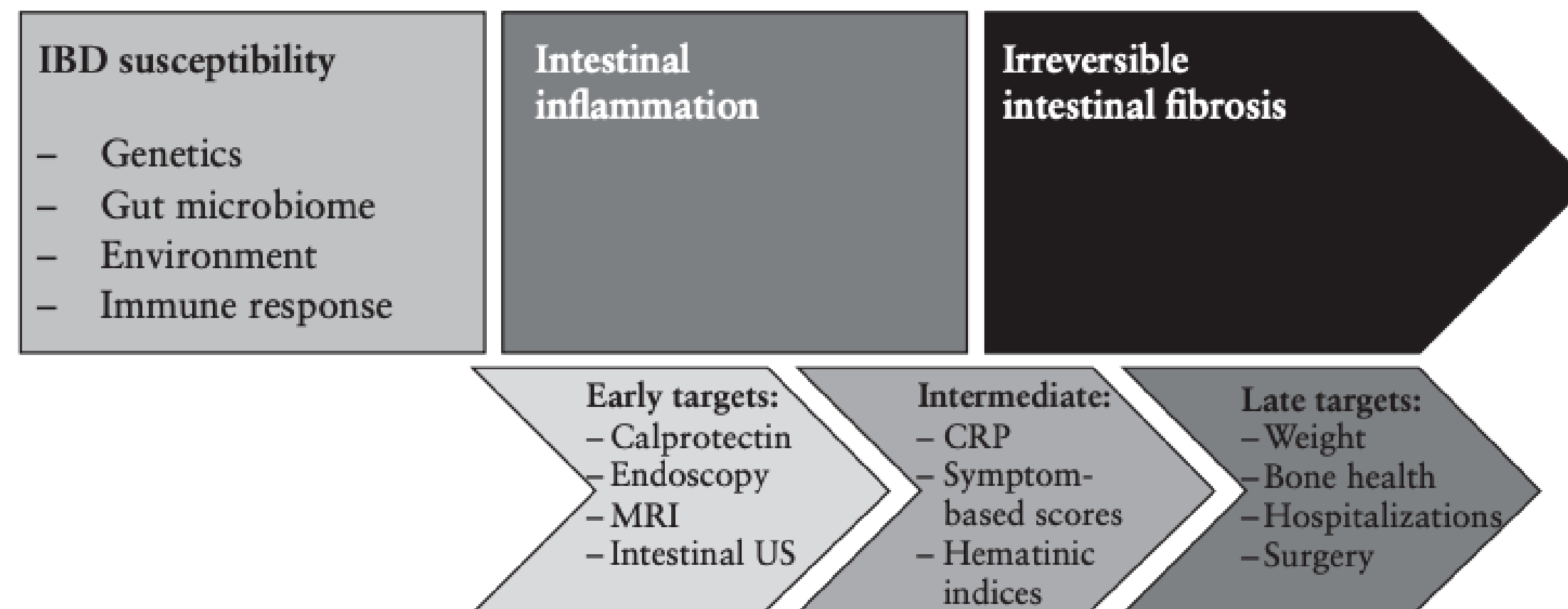
ECCO Guideline/Consensus Paper

ECCO-ESGAR Guideline for Diagnostic Assessment in IBD Part 1: Initial diagnosis, monitoring of known IBD, detection of complications

Statement 1.10. ECCO-ESGAR Diagnostics GL [2018]
 All newly diagnosed CD patients should undergo small bowel assessment [intestinal ultrasound, MR enterography and/or capsule endoscopy] [EL2]

Statement 2.3.4. ECCO-ESGAR Diagnostics GL [2018]
 Symptomatic small bowel disease can be investigated with MR enterography, IUS, and/or small bowel capsule endoscopy [SBCE] [EL2]

Statement 2.4.2. ECCO-ESGAR Diagnostics GL [2018]
 FC, IUS, MR enterography, and SBCE can be considered as non-invasive alternatives to detect postoperative recurrence, in particular after small bowel resection [EL2]



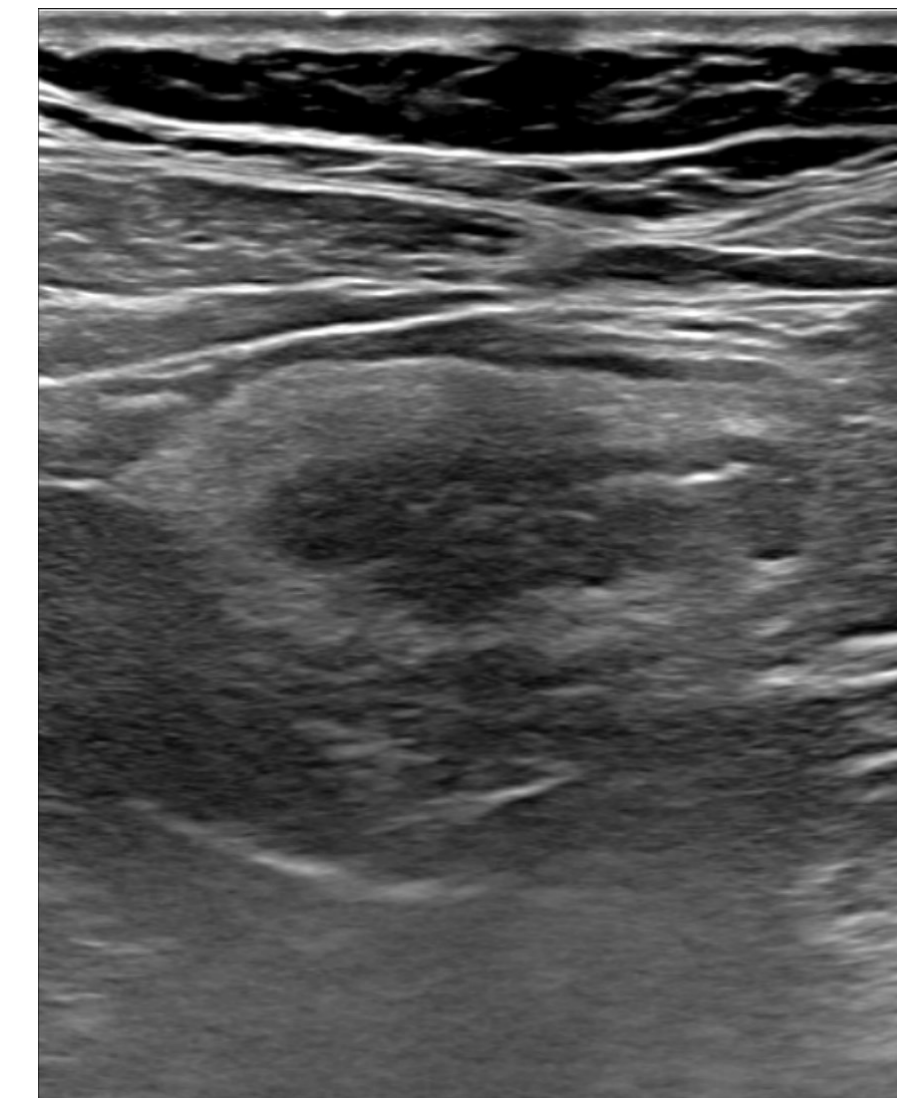
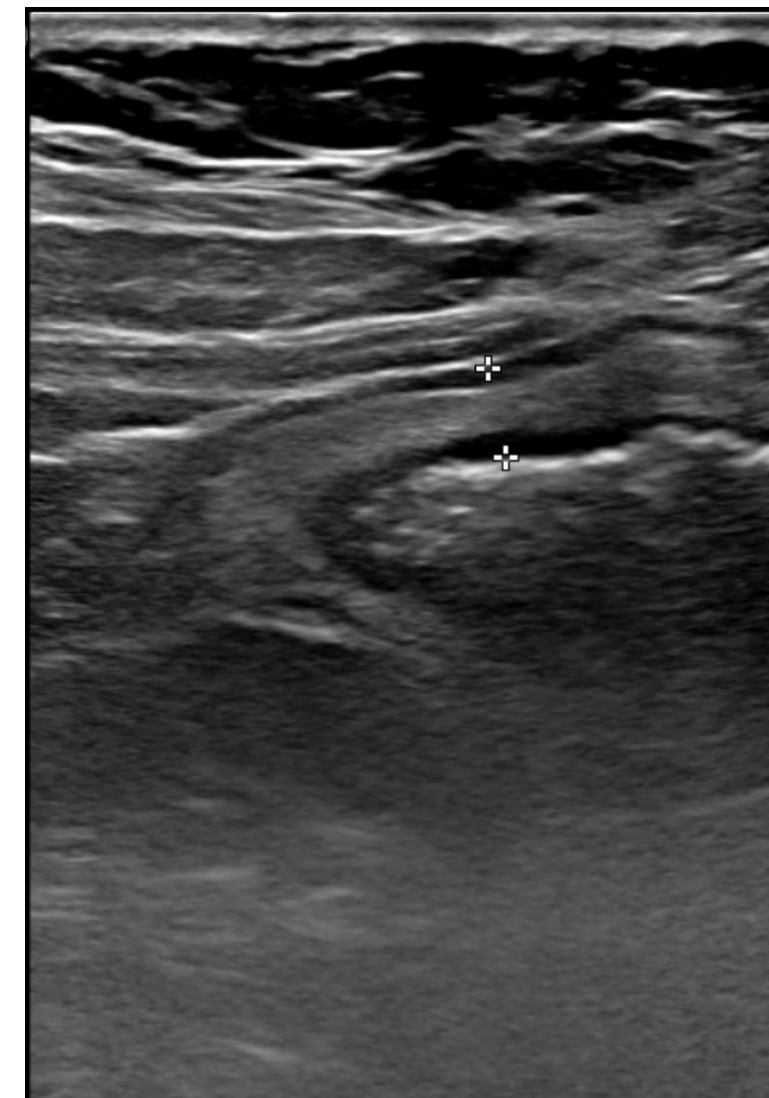Ecografía intestinal: Enfermedad Inflamatoria Intestinal

- Experiencia en el control de Enfermedad inflamatoria intestinal
- Evaluación de fibrosis intestinal
- Evaluación de actividad inflamatoria
- Elastografía intestinal

Operador Experto

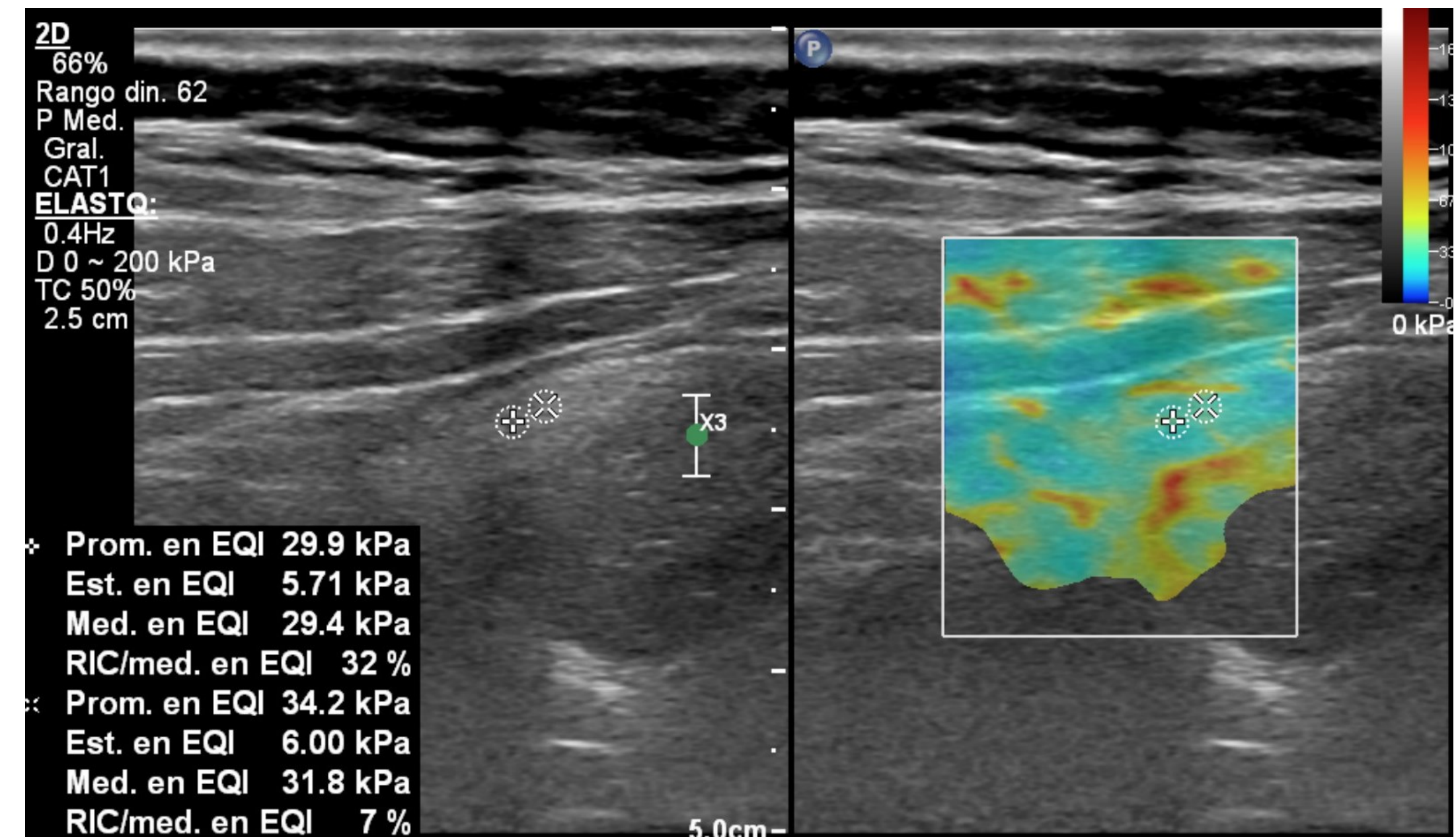
Examen EnteroRM


Antecedentes



Elastografía intestinal: Enfermedad Inflamatoria Intestinal

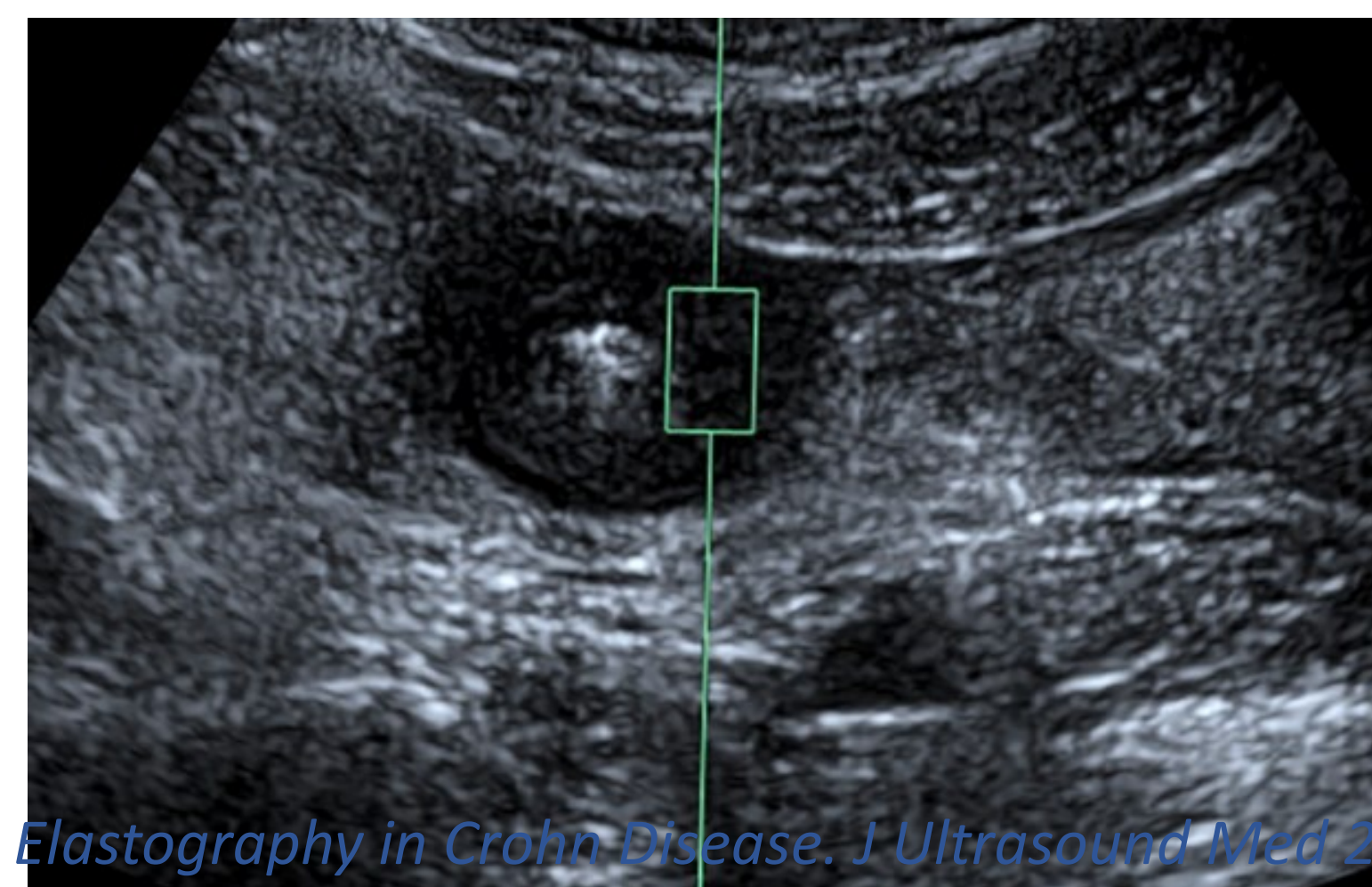
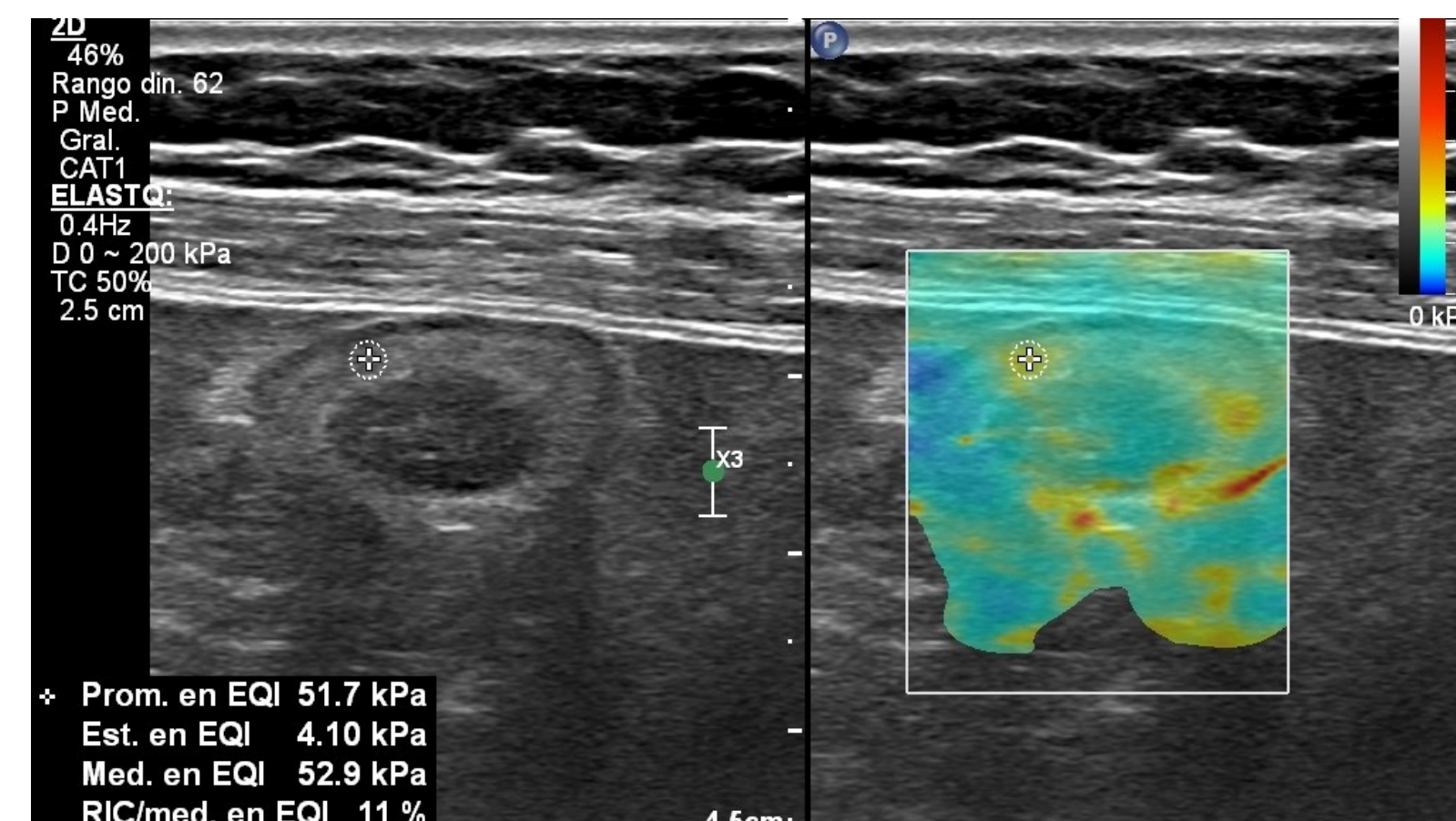
- Evaluación de fibrosis intestinal
- Elastografía por deformación:
 - Difícil de realizar
 - Limitada por peristaltismo
 - Dificultad para realizar compresión mecánica por movilidad de asas
- Elastografía Onda de corte
 - Mediciones objetivas y reproducibles






Elastografía intestinal: Enfermedad Inflamatoria Intestinal ¿cómo hacerla?

- 10 ROI
- Axial o longitudinal
- Control de calidad de la muestra:
 - IQR/Med:
 - < 30% kPa
 - < 15% m/s
- Valores de corte no del todo claros actualmente.

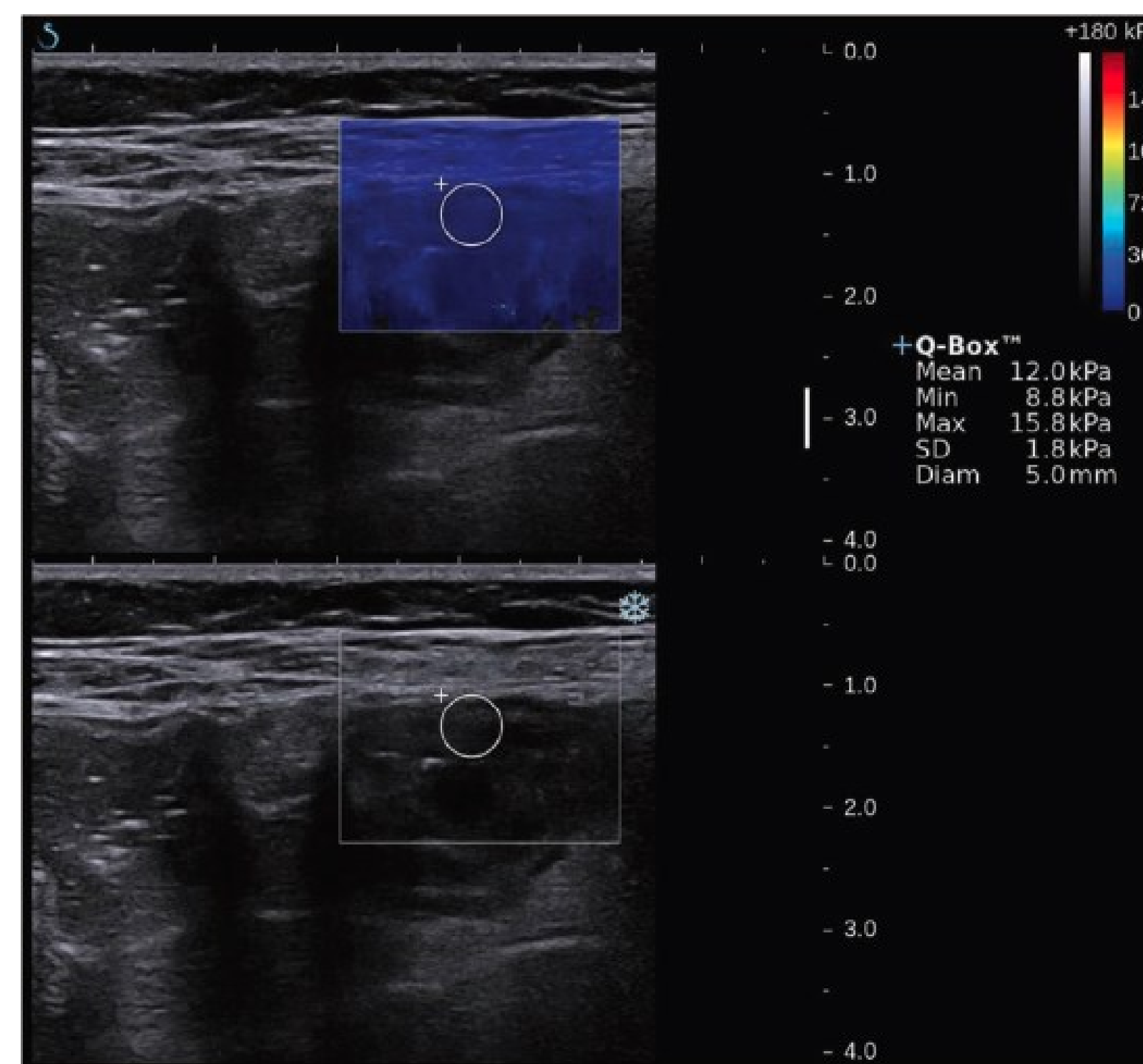




Real-Time Shear Wave Ultrasound Elastography Differentiates Fibrotic from Inflammatory Strictures in Patients with Crohn's Disease

Yu-jun Chen, MD,^{*,*} Ren Mao, MD, PhD,^{*,†} Xue-hua Li, MD,[‡] Qing-hua Cao, MD,[§]
Zhi-hui Chen, MD, PhD,[¶] Bao-xian Liu, MD,^{*} Shu-ling Chen, MD,^{*} Bai-li Chen, MD,[†] Yao He, MD,[†]
Zhi-rong Zeng, MD,[†] Shomron Ben-Horin, MD,^{†,**} Jordi Rimola, MD,^{††} Florian Rieder, MD, PhD,^{##}
Xiao-yan Xie, MD,^{*} and Min-hu Chen, MD, PhD[†]

- 35 pactes
- Eco convencional para evaluar
 - Grosor parietal
 - Presencia de patrón estratificado
 - Puntaje de Limberg
 - I: engrosamiento pared intestinal (<3 mm) sin vascularización.
 - II: engrosamiento pared intestinal con leve vascularización.
 - III: engrosamiento pared intestinal con mayor vascularización
 - IV: engrosamiento pared intestinal con vascularización elevada que se extiende desde el mesenterio.






Real-Time Shear Wave Ultrasound Elastography Differentiates Fibrotic from Inflammatory Strictures in Patients with Crohn's Disease

Yu-jun Chen, MD,^{*,*} Ren Mao, MD, PhD,^{*,†} Xue-hua Li, MD,[‡] Qing-hua Cao, MD,[§]
 Zhi-hui Chen, MD, PhD,[¶] Bao-xian Liu, MD,^{*} Shu-ling Chen, MD,^{*} Bai-li Chen, MD,[†] Yao He, MD,[†]
 Zhi-rong Zeng, MD,[†] Shomron Ben-Horin, MD,^{†,**} Jordi Rimola, MD,^{††} Florian Rieder, MD, PhD,^{##}
 Xiao-yan Xie, MD,^{*} and Min-hu Chen, MD, PhD[†]

TABLE 3: Conventional Ultrasound and Shear-Wave Elastography Findings in Different Grades of Intestinal Inflammation and Fibrosis

	Grade of Inflammation			P	Grade of Fibrosis			P
	mild (no. = 5)	moderate (no. = 11)	severe (no. = 19)		mild (no. = 3)	moderate (no. = 12)	severe (no. = 20)	
Bowel thickness	11.5 ± 2.7	10.0 ± 3.9	10.7 ± 3.1	0.699	7.39 ± 2.8	9.9 ± 2.4	10.9 ± 3.7	0.392
Proximal bowel dilation	1	4	6	0.808	1	4	6	0.451
Limberg classification _a				0.001				0.373
I	1	0	0		0	0	1	
II	4	3	1		2	1	5	
III	0	6	7		3	5	5	
IV	0	2	11		4	6	3	
Stratified echo pattern	1	8	7	0.106	2	6	8	0.290
SWE value (mean)	19.3 ± 1.6	20.9 ± 9.0	20.3 ± 4.6	0.380	14.4 ± 2.1	17.4 ± 3.8	23.0 ± 6.3	0.008



Real-Time Shear Wave Ultrasound Elastography Differentiates Fibrotic from Inflammatory Strictures in Patients with Crohn's Disease

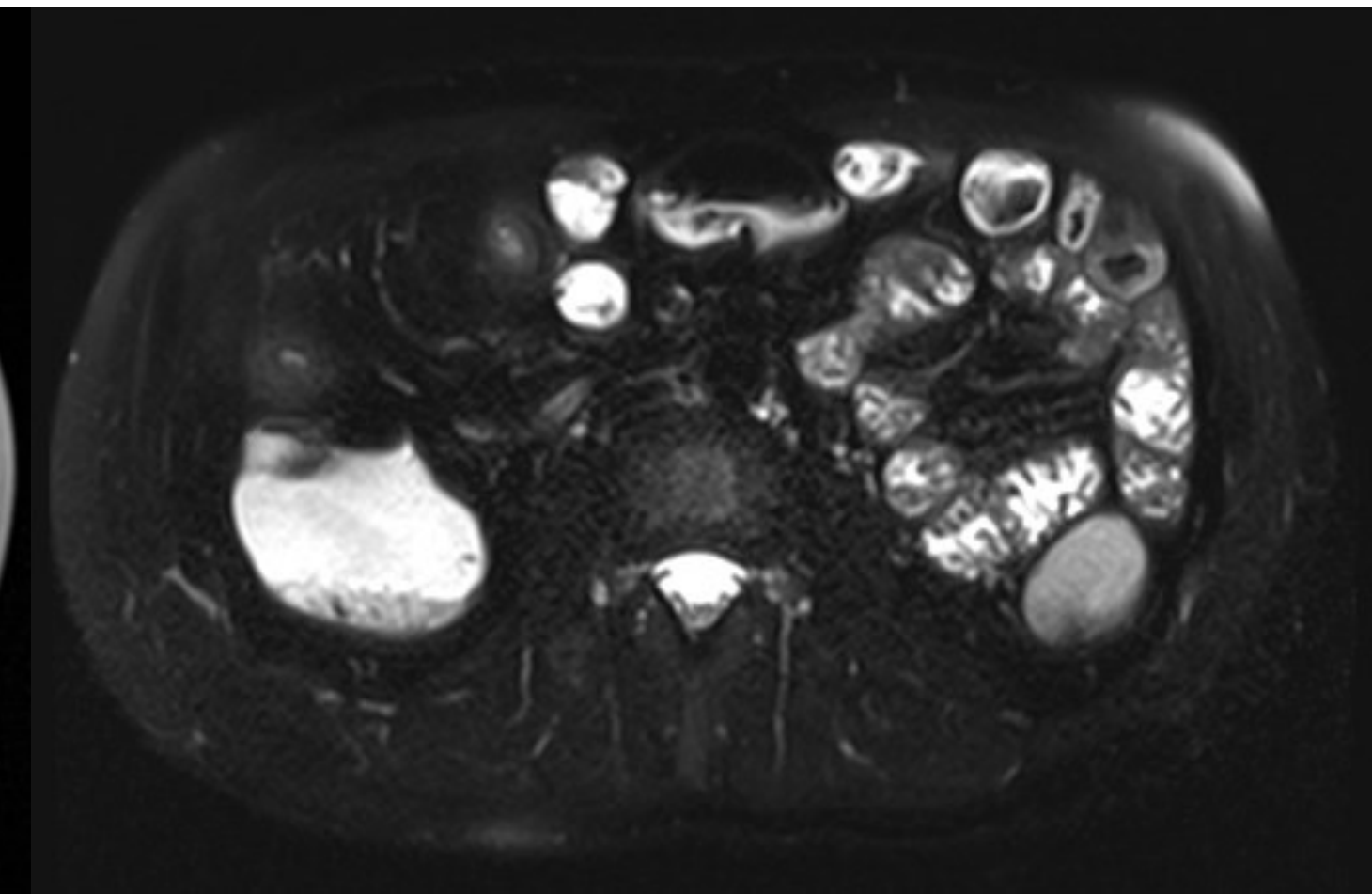
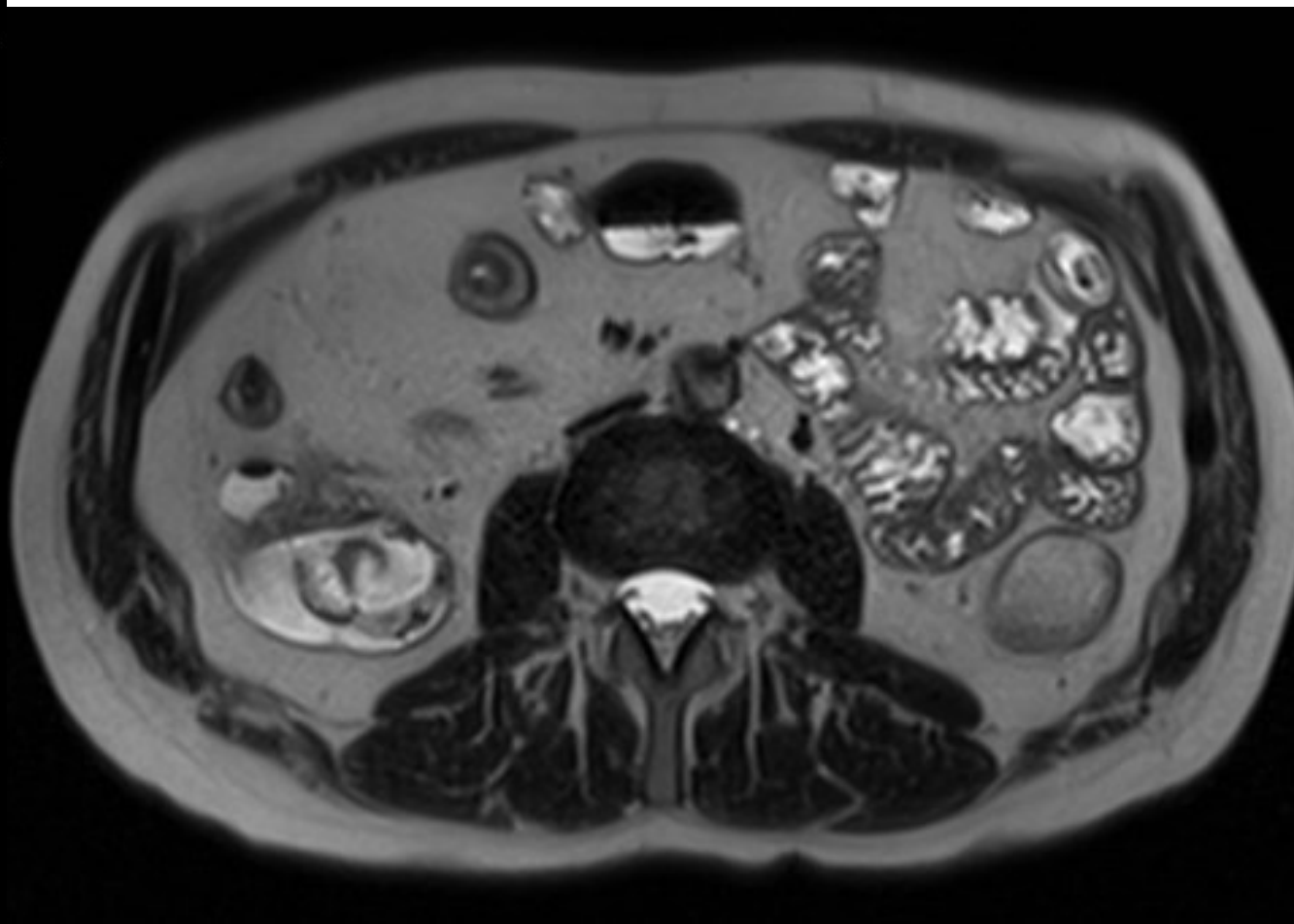
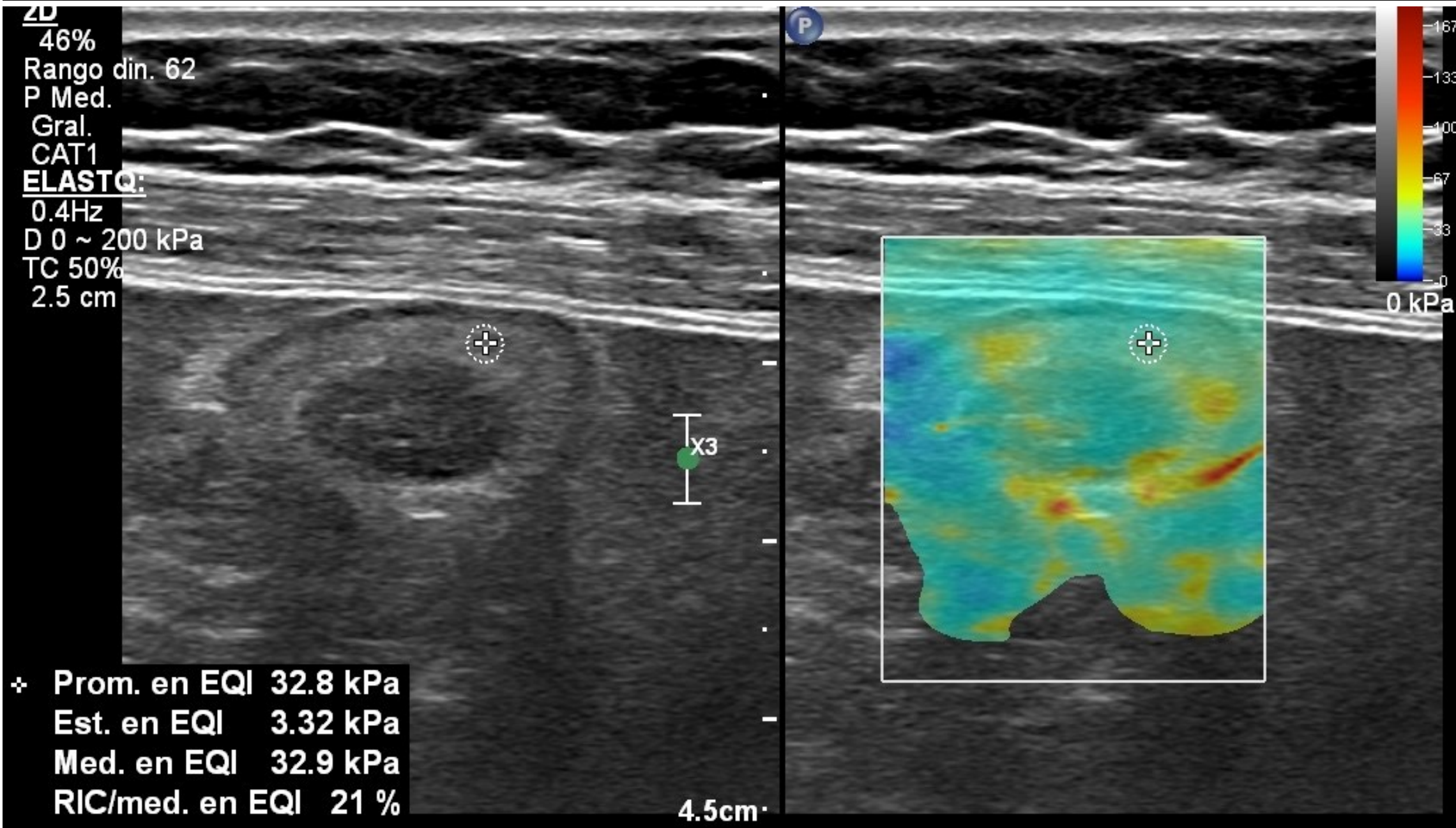
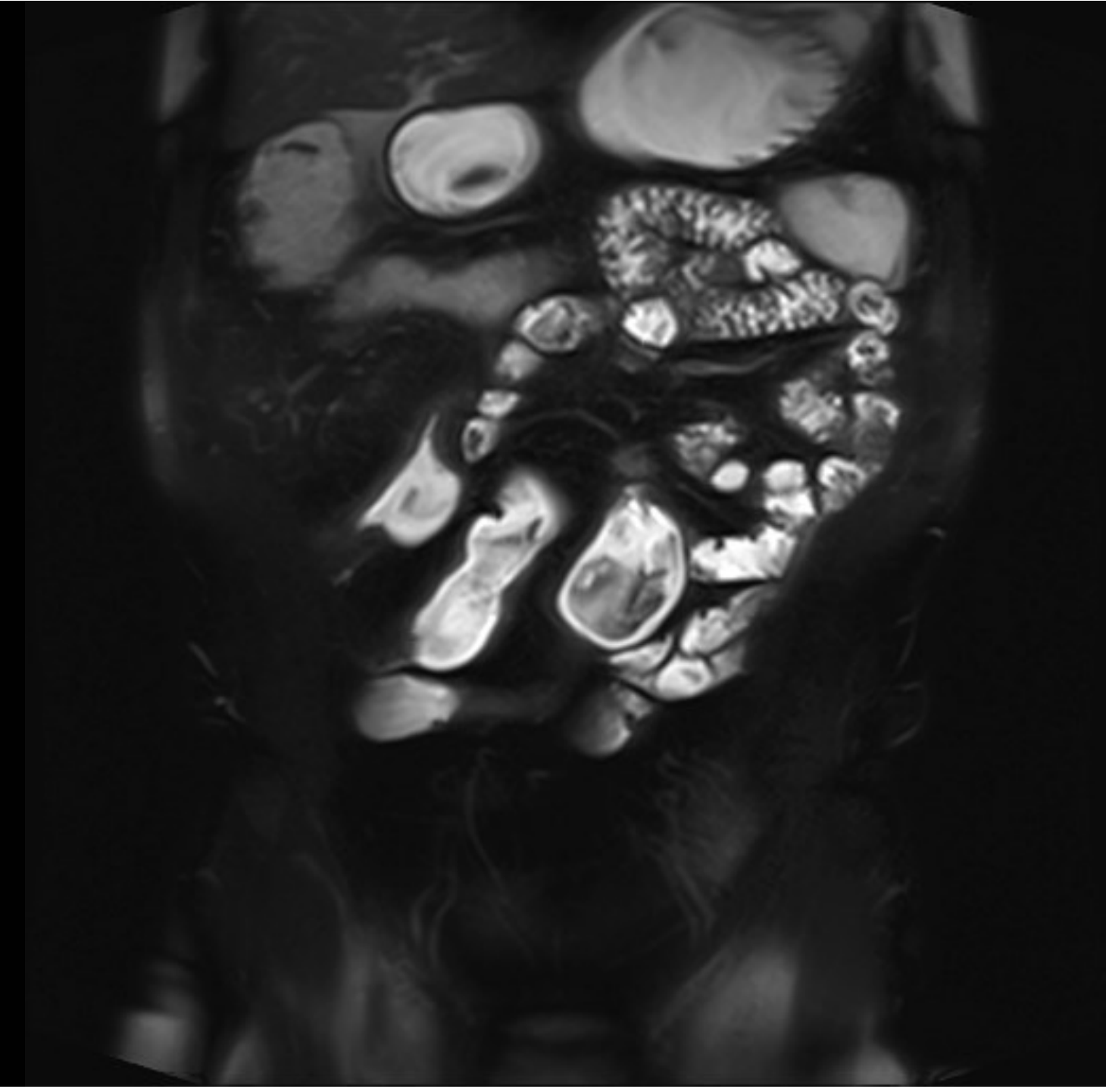
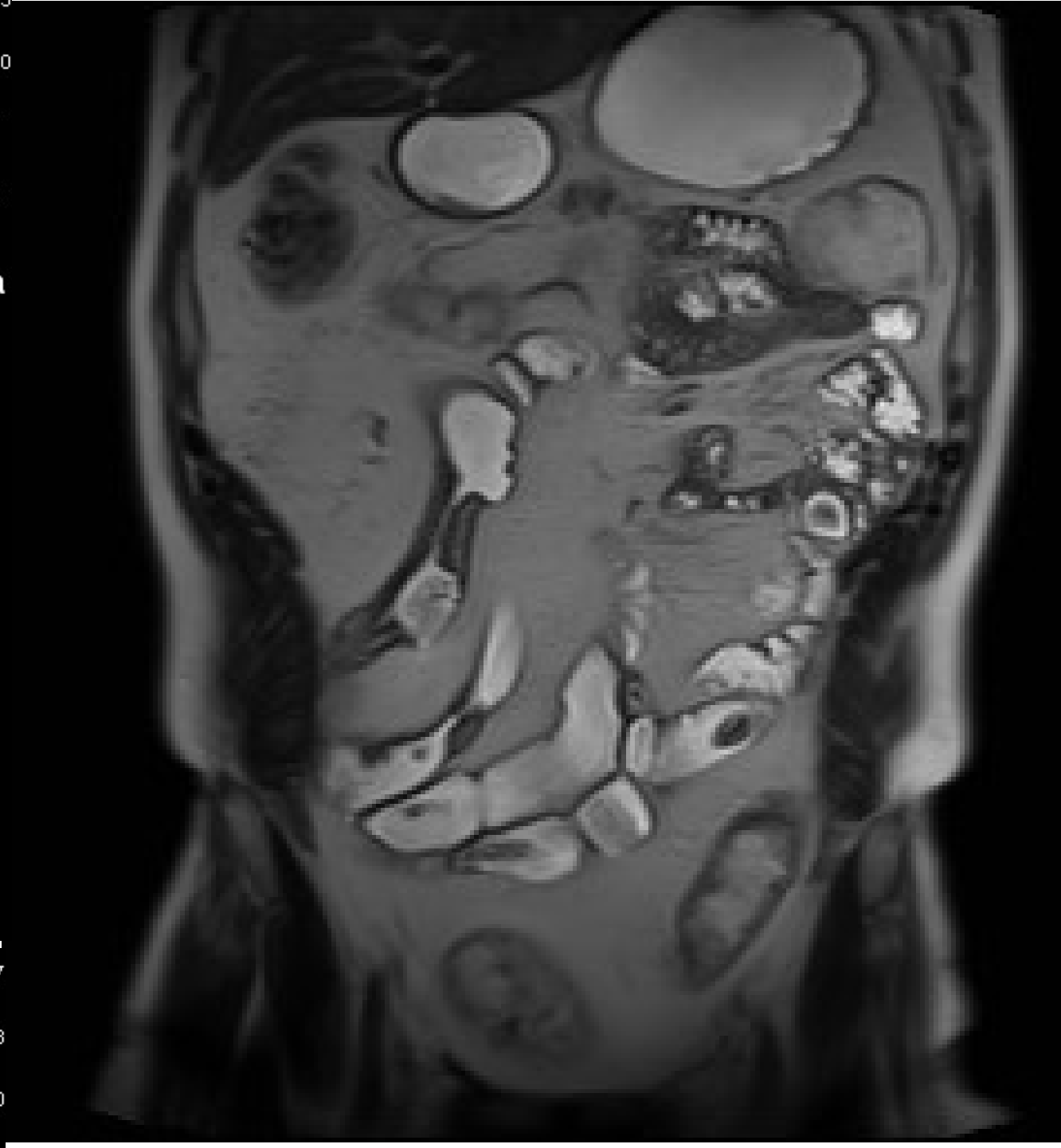
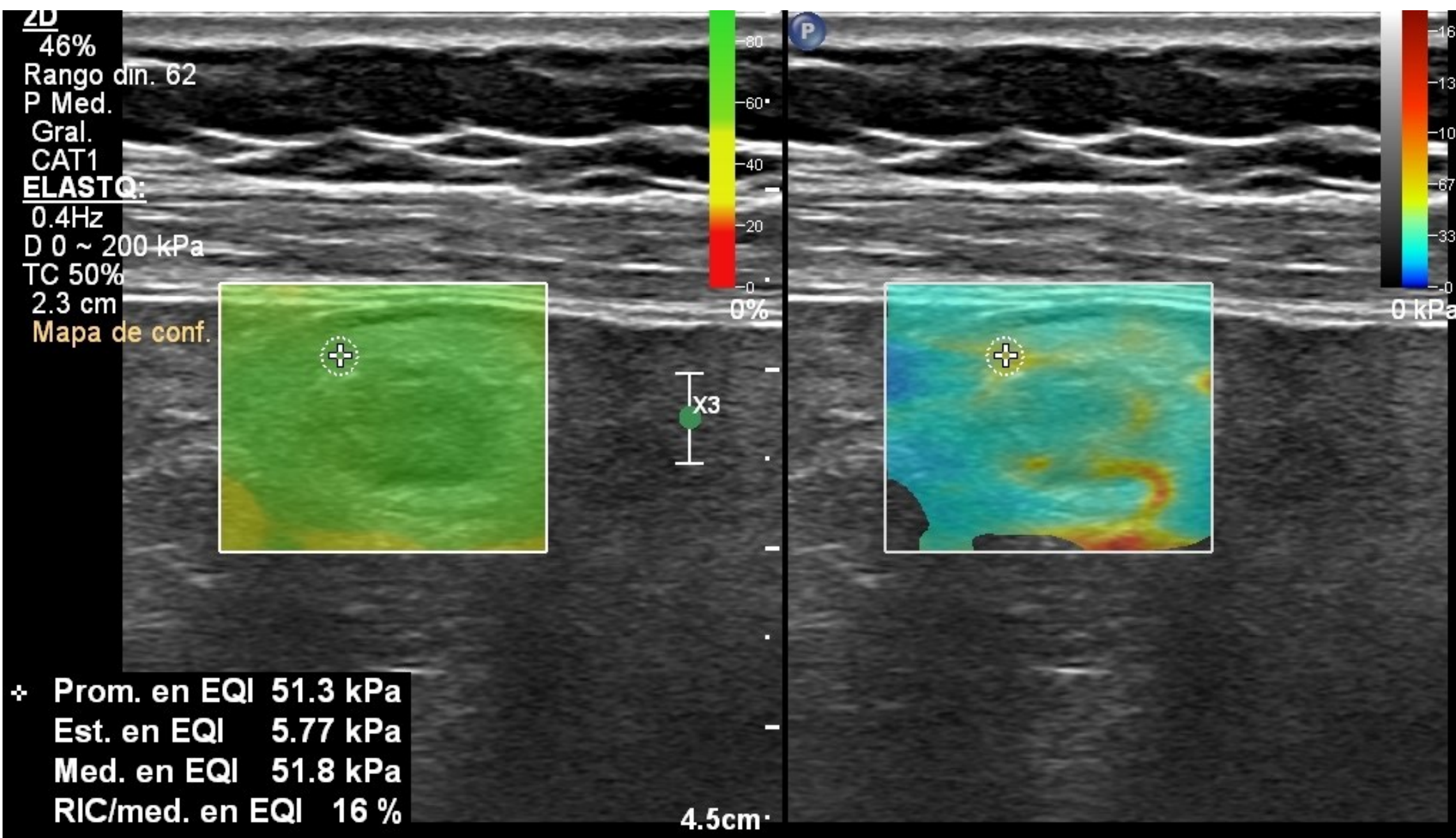


Yu-jun Chen, MD,^{*,*} Ren Mao, MD, PhD,^{*,†} Xue-hua Li, MD,[‡] Qing-hua Cao, MD,[§]
Zhi-hui Chen, MD, PhD,[¶] Bao-xian Liu, MD,^{*} Shu-ling Chen, MD,^{*} Bai-li Chen, MD,[†] Yao He, MD,[†]
Zhi-rong Zeng, MD,[†] Shomron Ben-Horin, MD,^{†,**} Jordi Rimola, MD,^{††} Florian Rieder, MD, PhD,^{##}
Xiao-yan Xie, MD,^{*} and Min-hu Chen, MD, PhD[†]

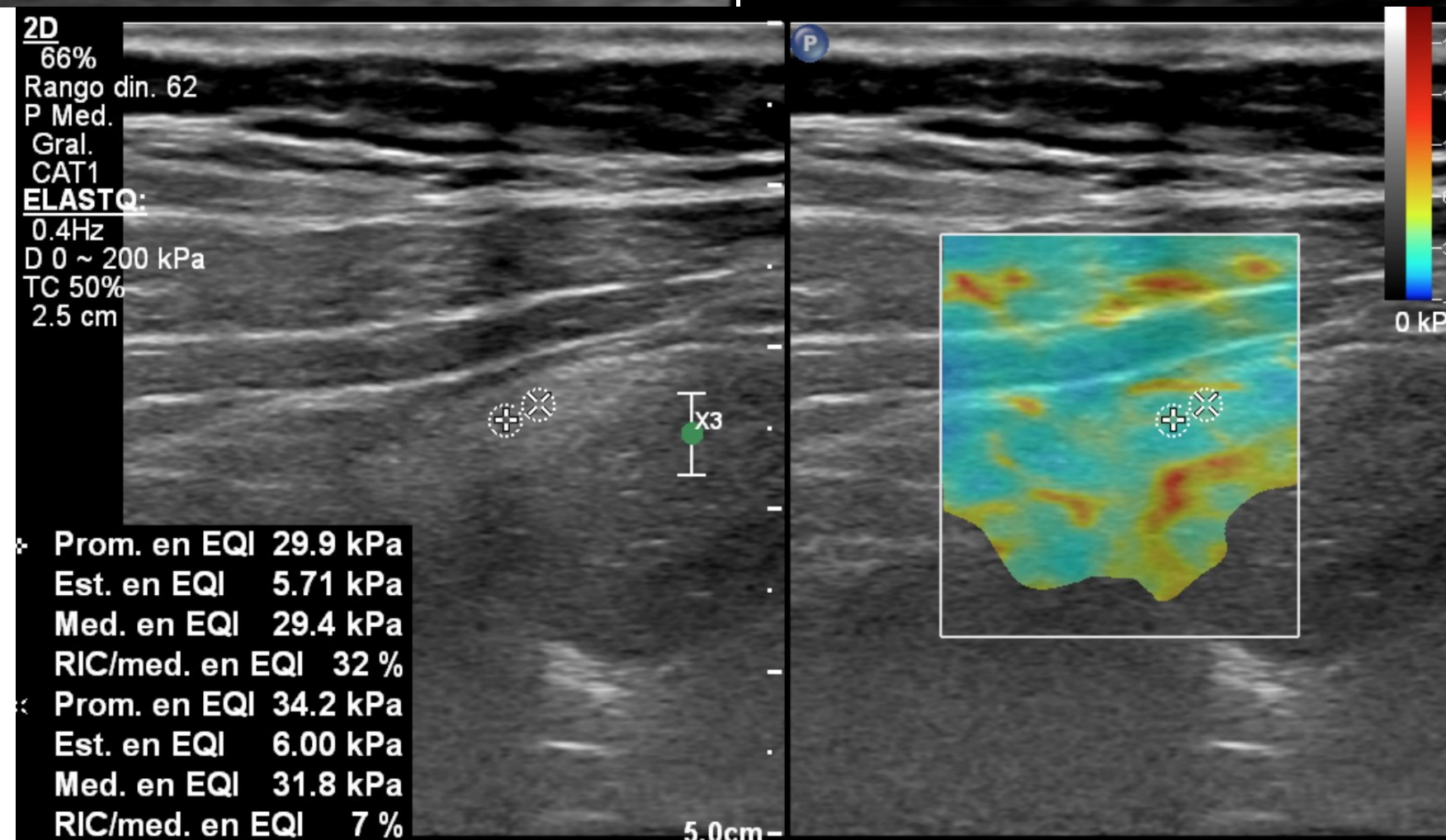
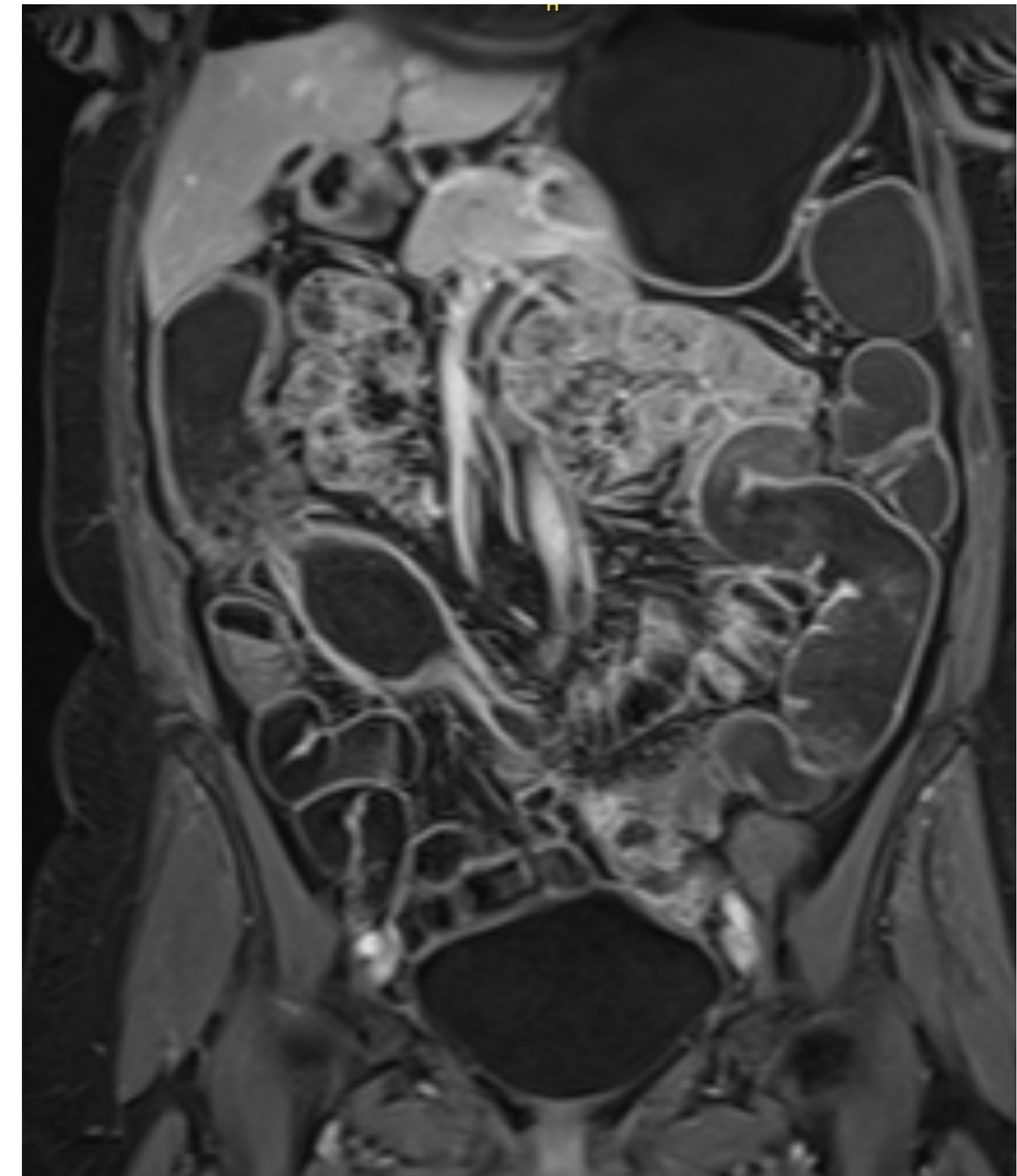
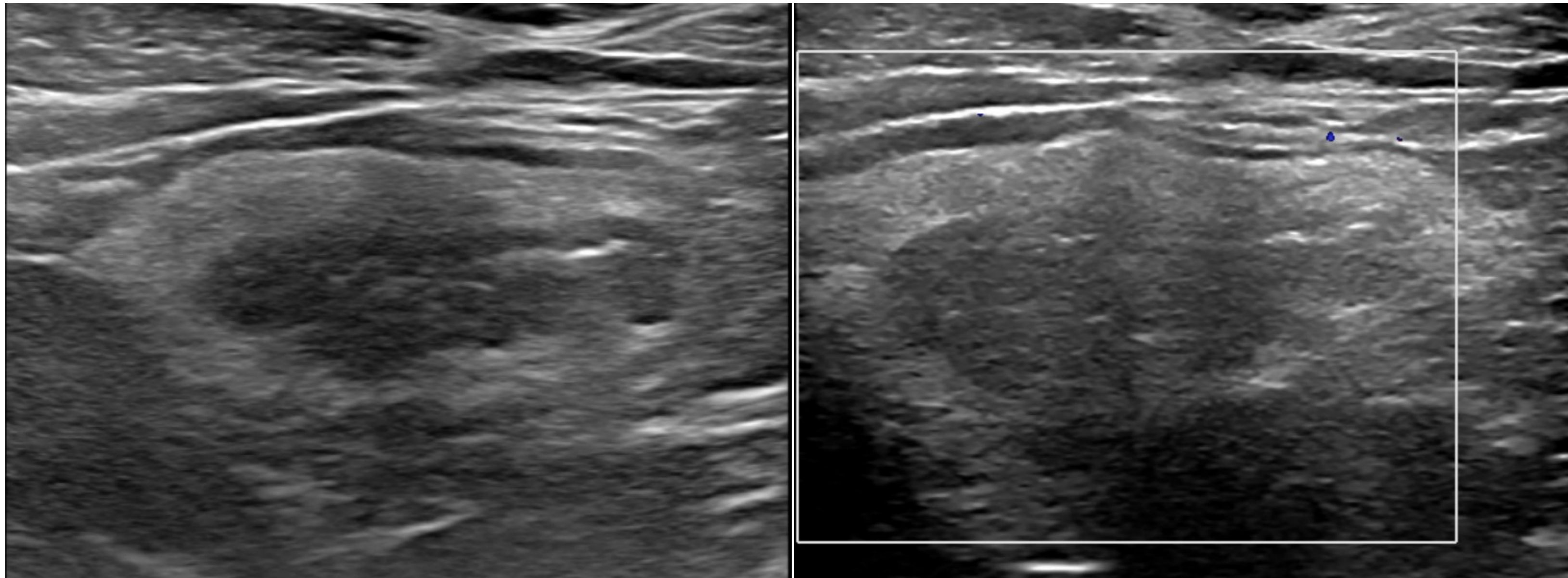
TABLE 4: Stricture Classification Based on Grade of Inflammation and Fibrosis on Bowel Ultrasound

	SWE value < 22.55 Kpa	SWE value ≥22.55 Kpa
Limberg _a I/II	Low inflammation Low fibrosis (n = 2)	Low inflammation Marked fibrosis (n = 7)
Limberg _b III/IV	Low fibrosis Severe inflammation (n = 16)	Severe inflammation Marked fibrosis (n = 10)

Kappa de Cohen; P < 0,001, K, 0,536

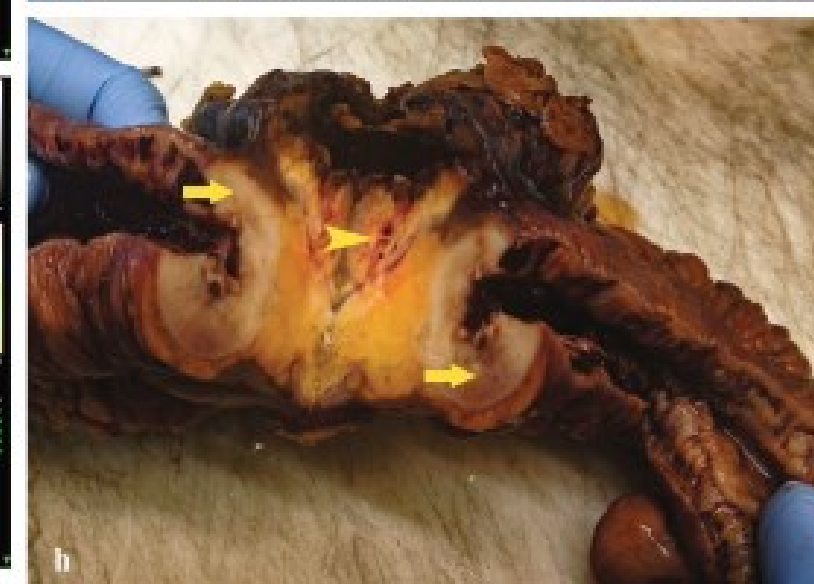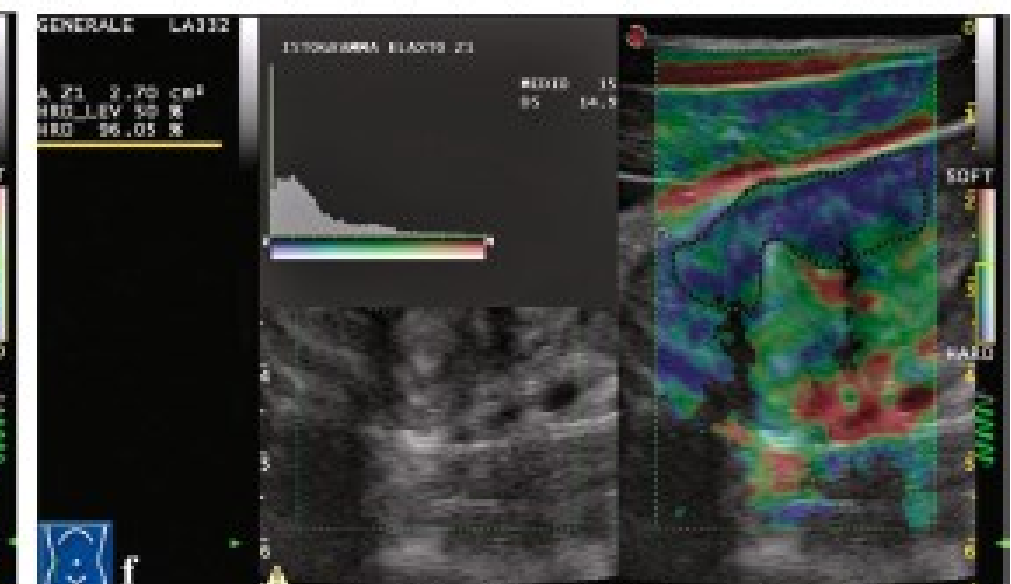
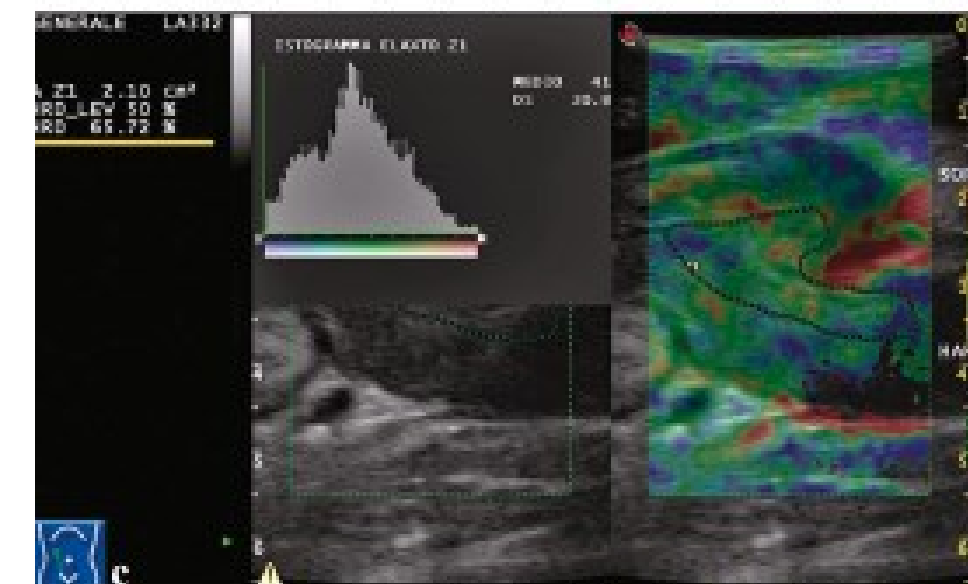
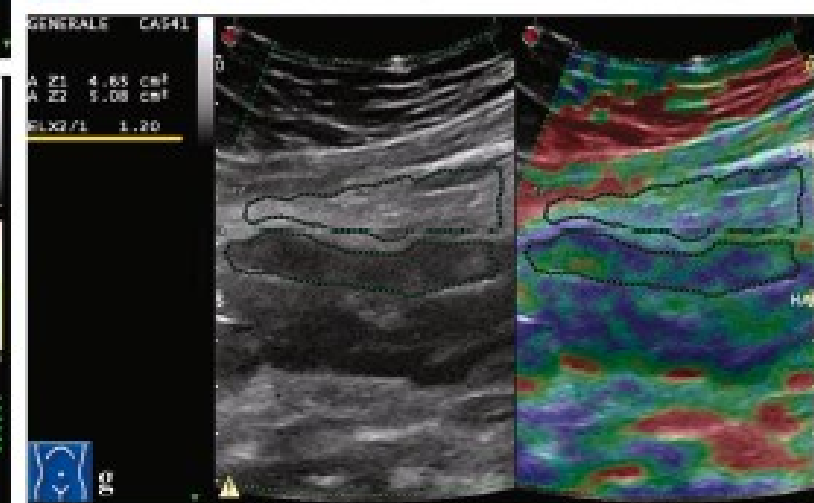
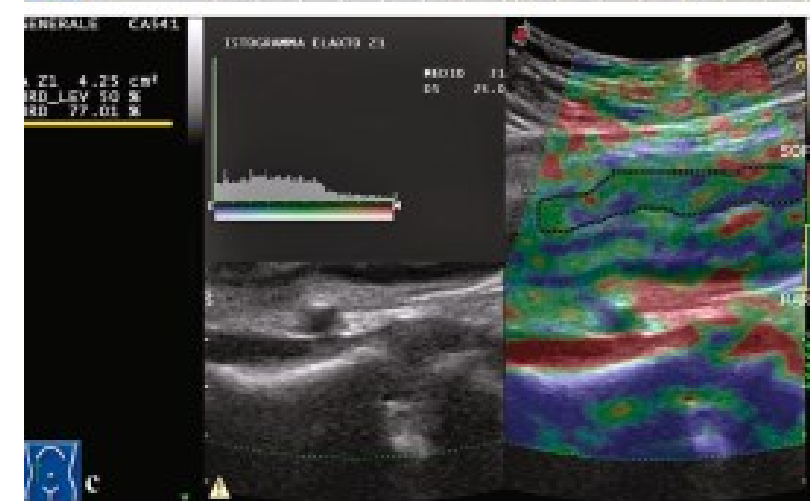
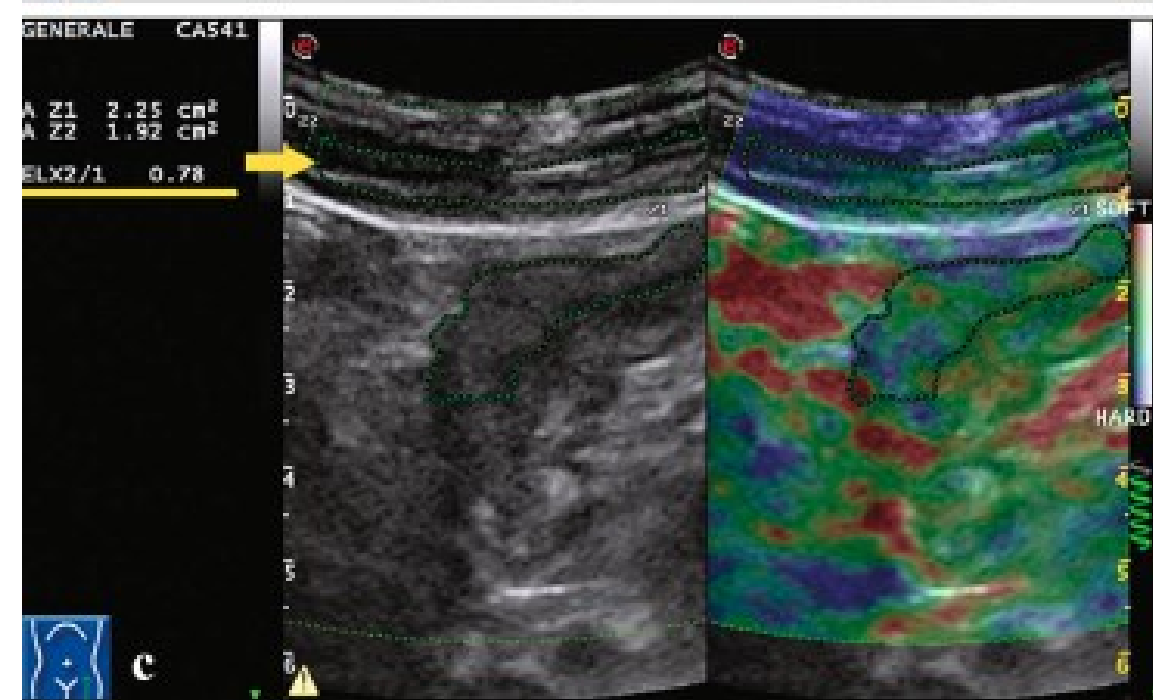
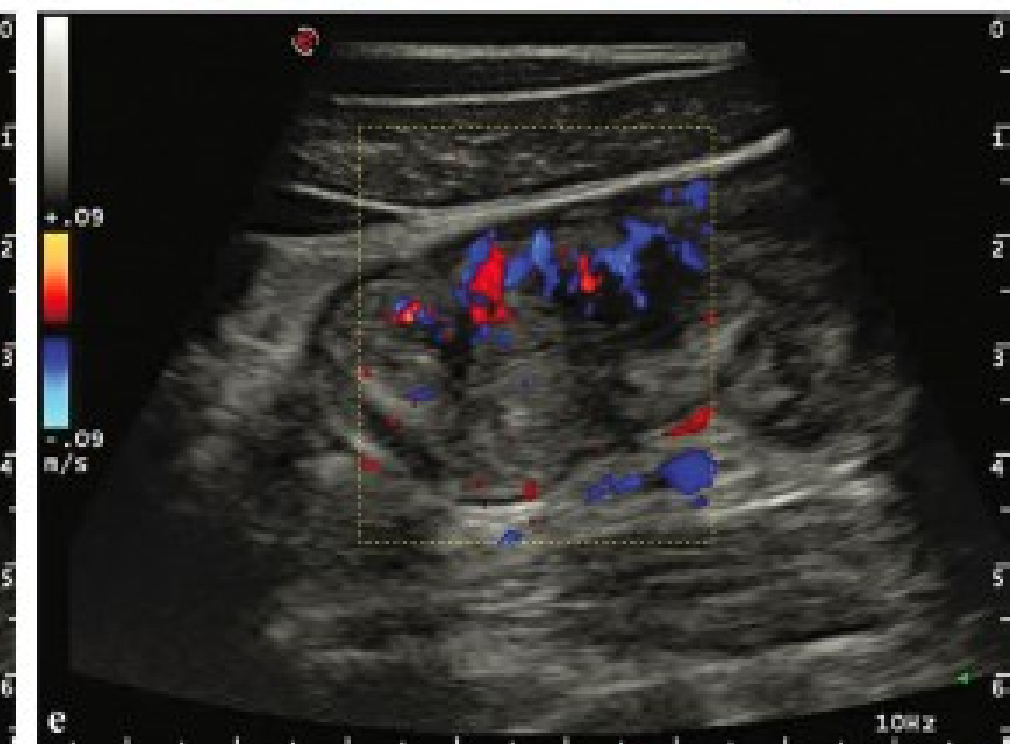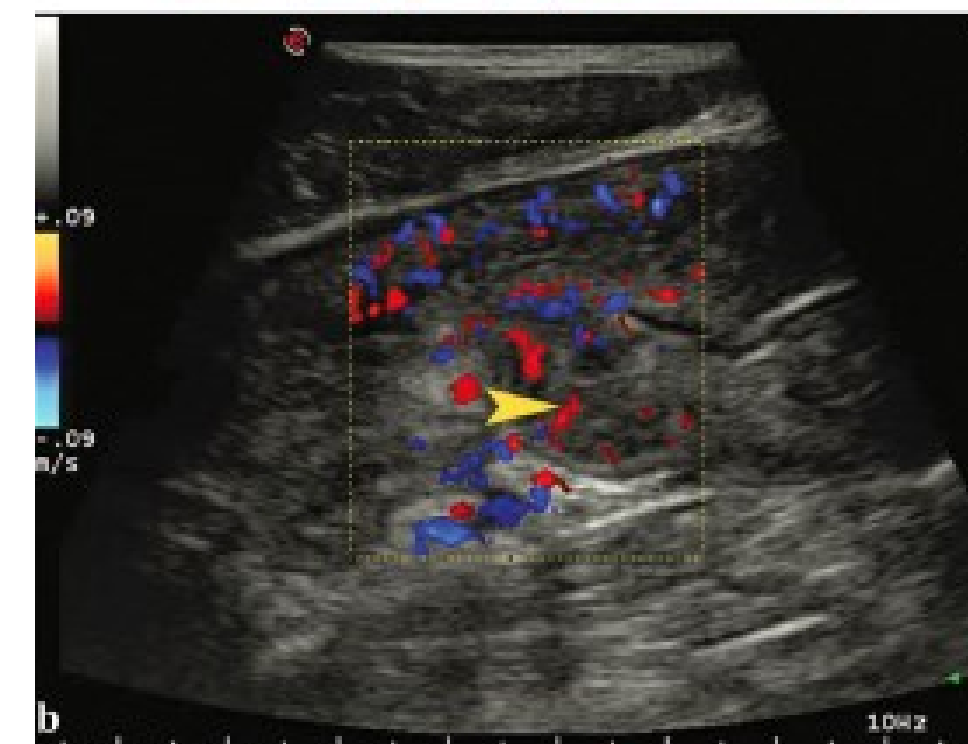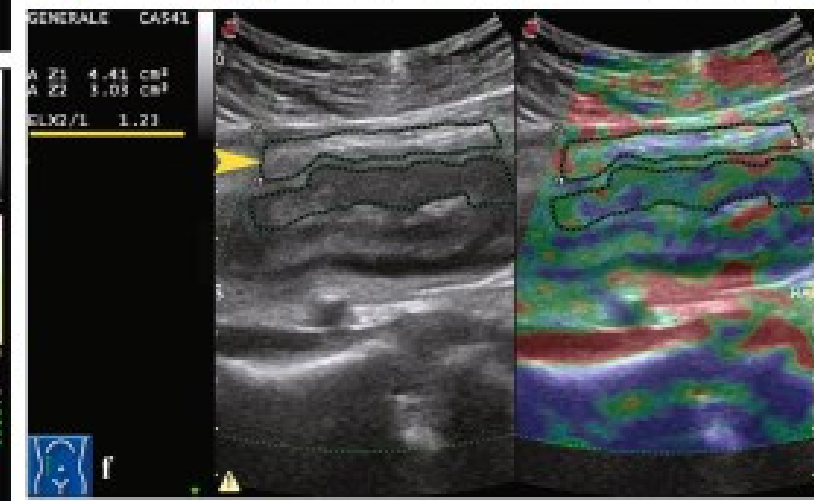
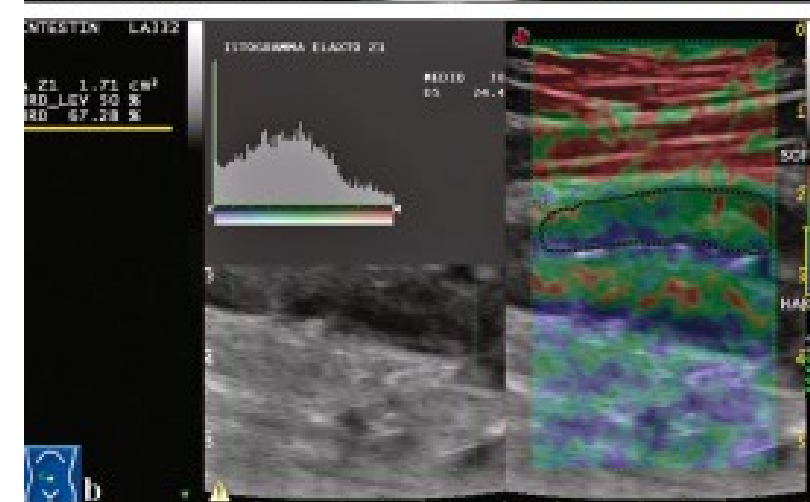
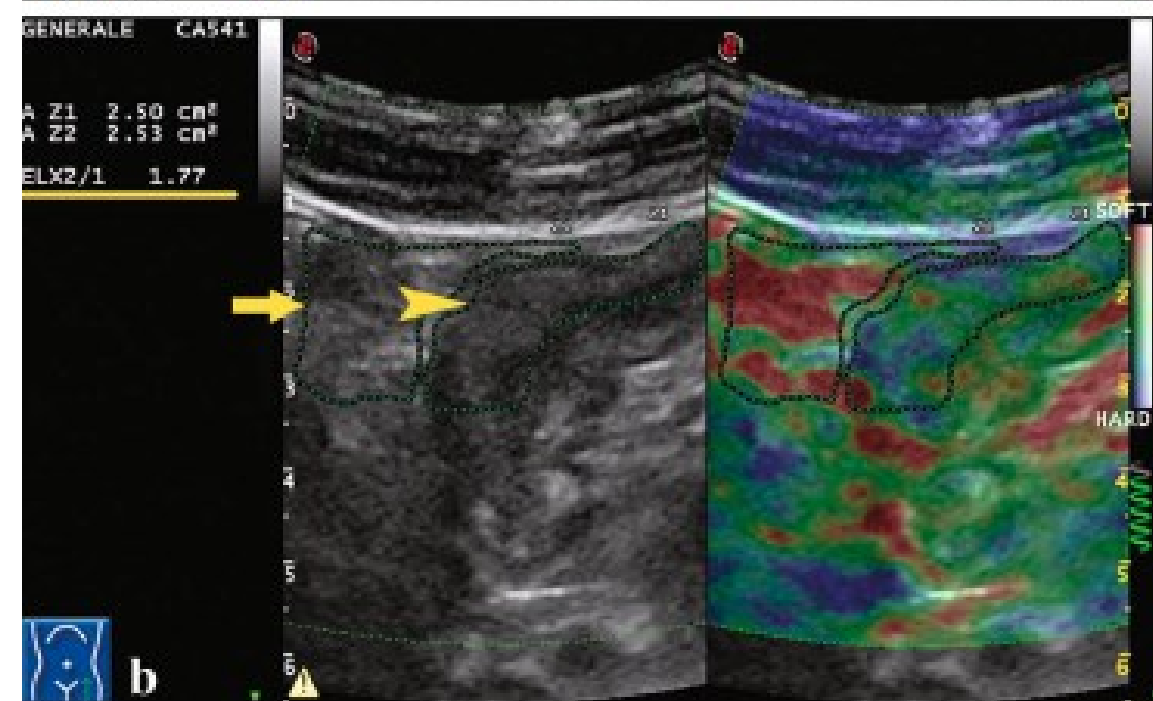
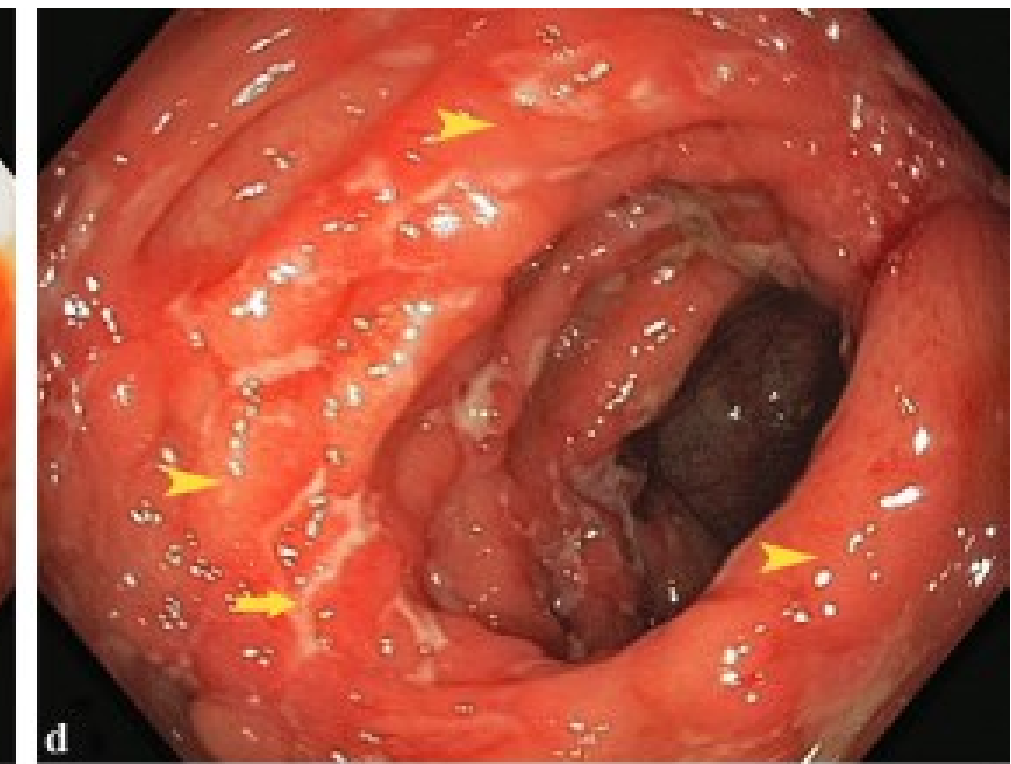
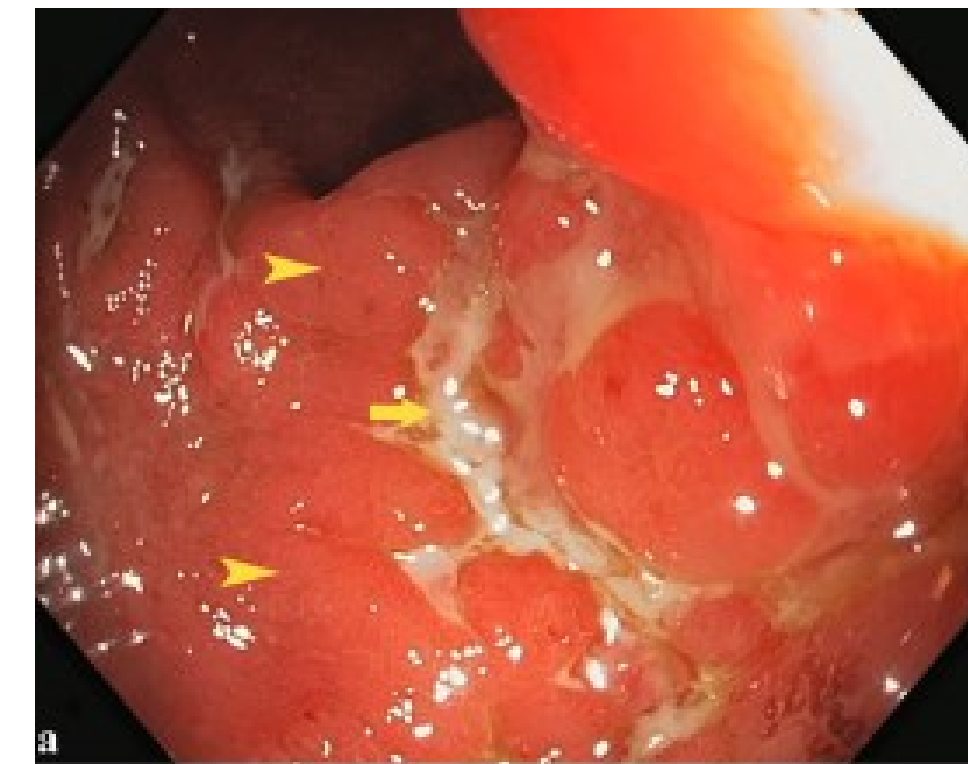
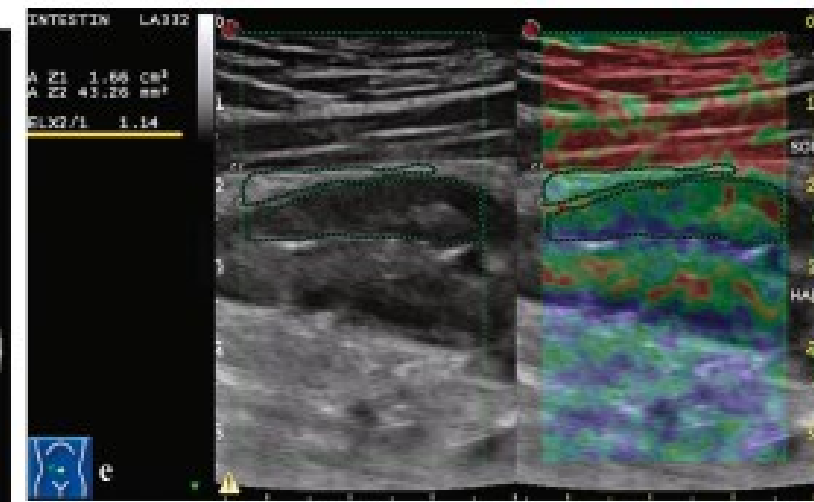
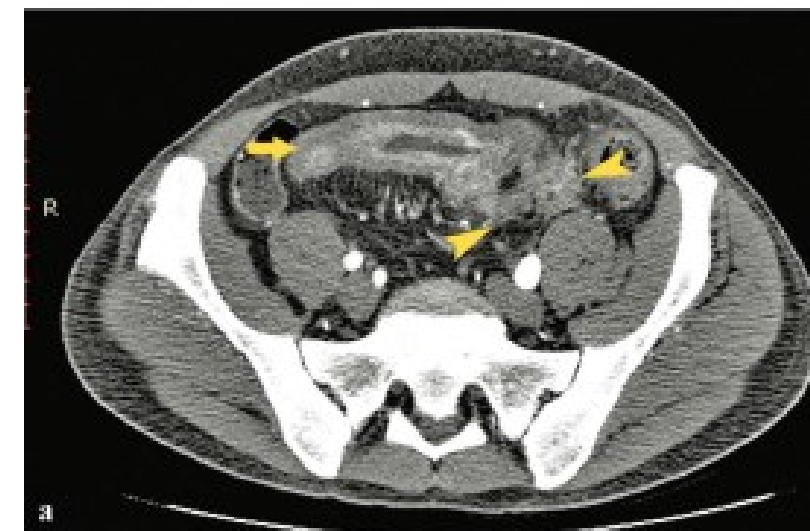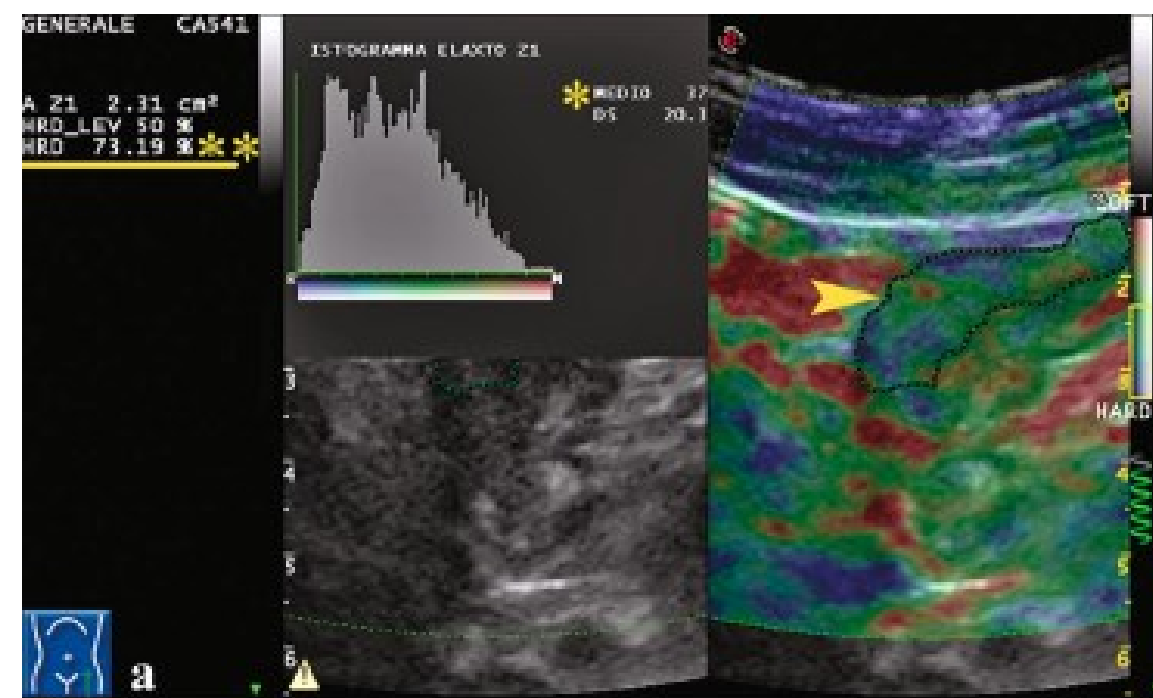


Ecografía intestinal: Enfermedad Inflamatoria Intestinal

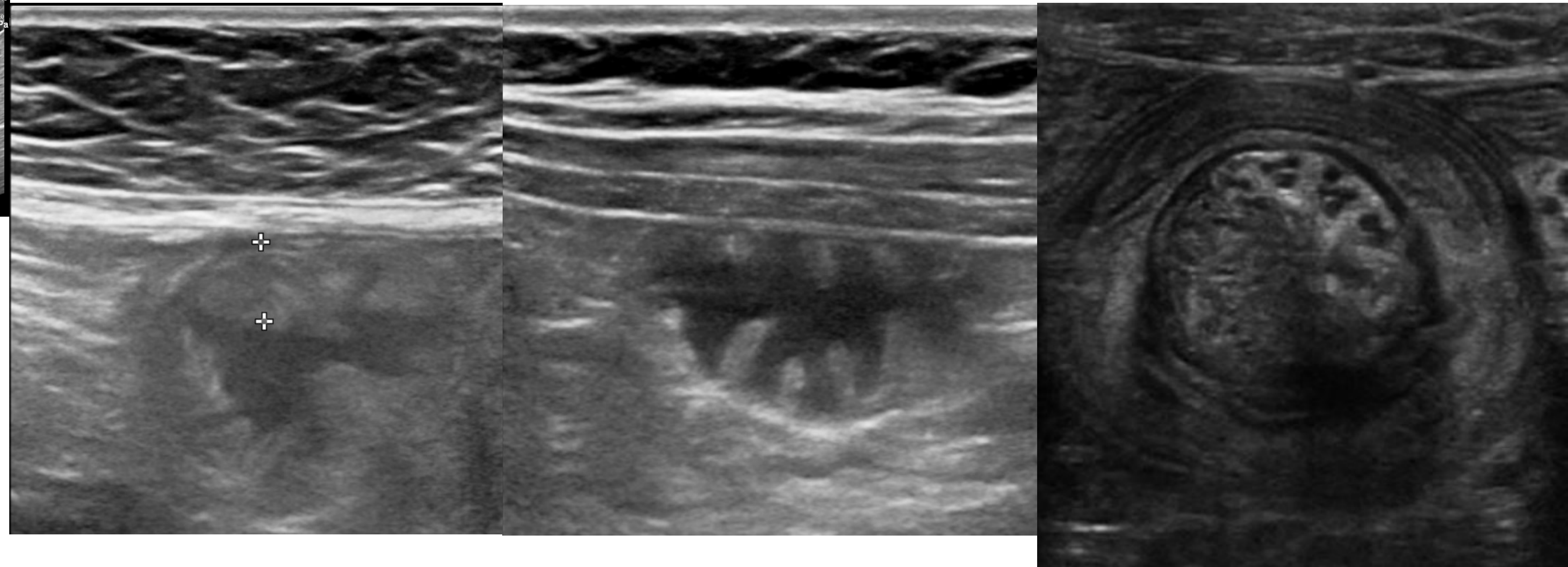
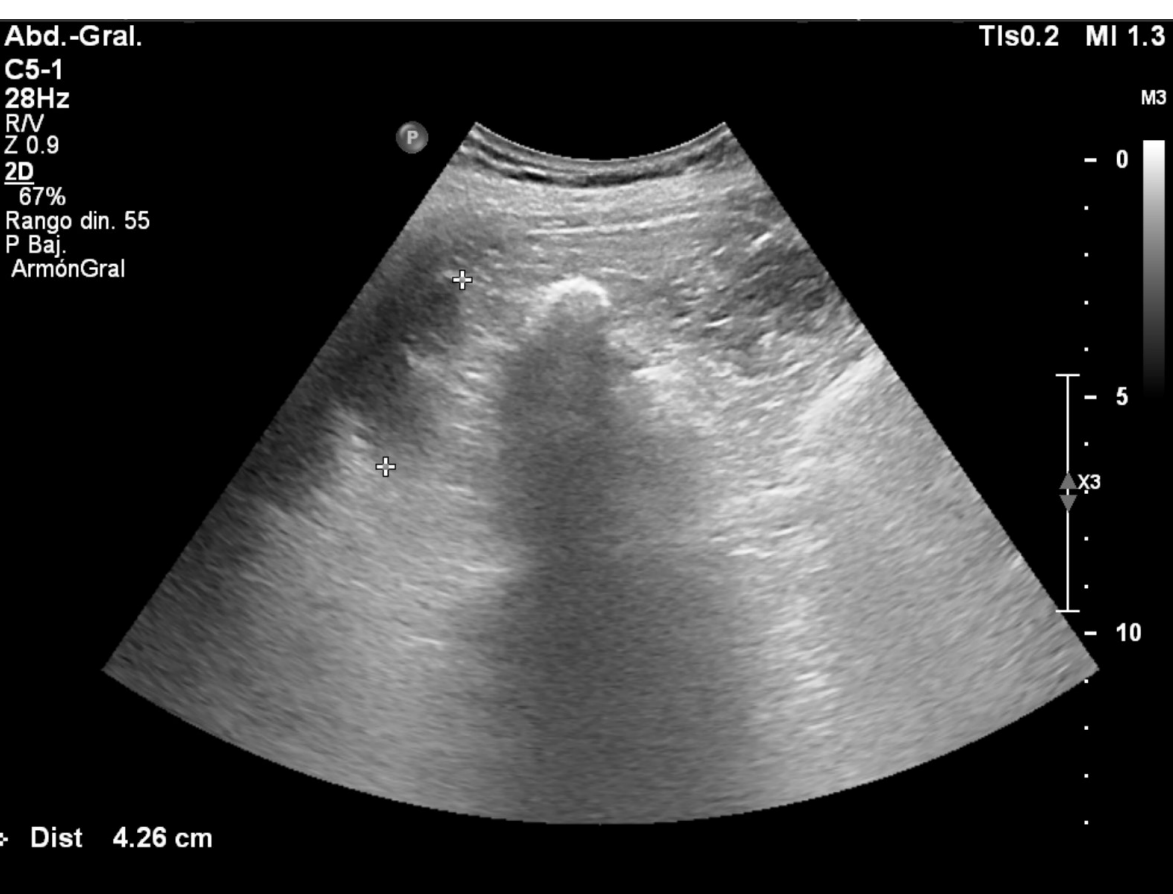
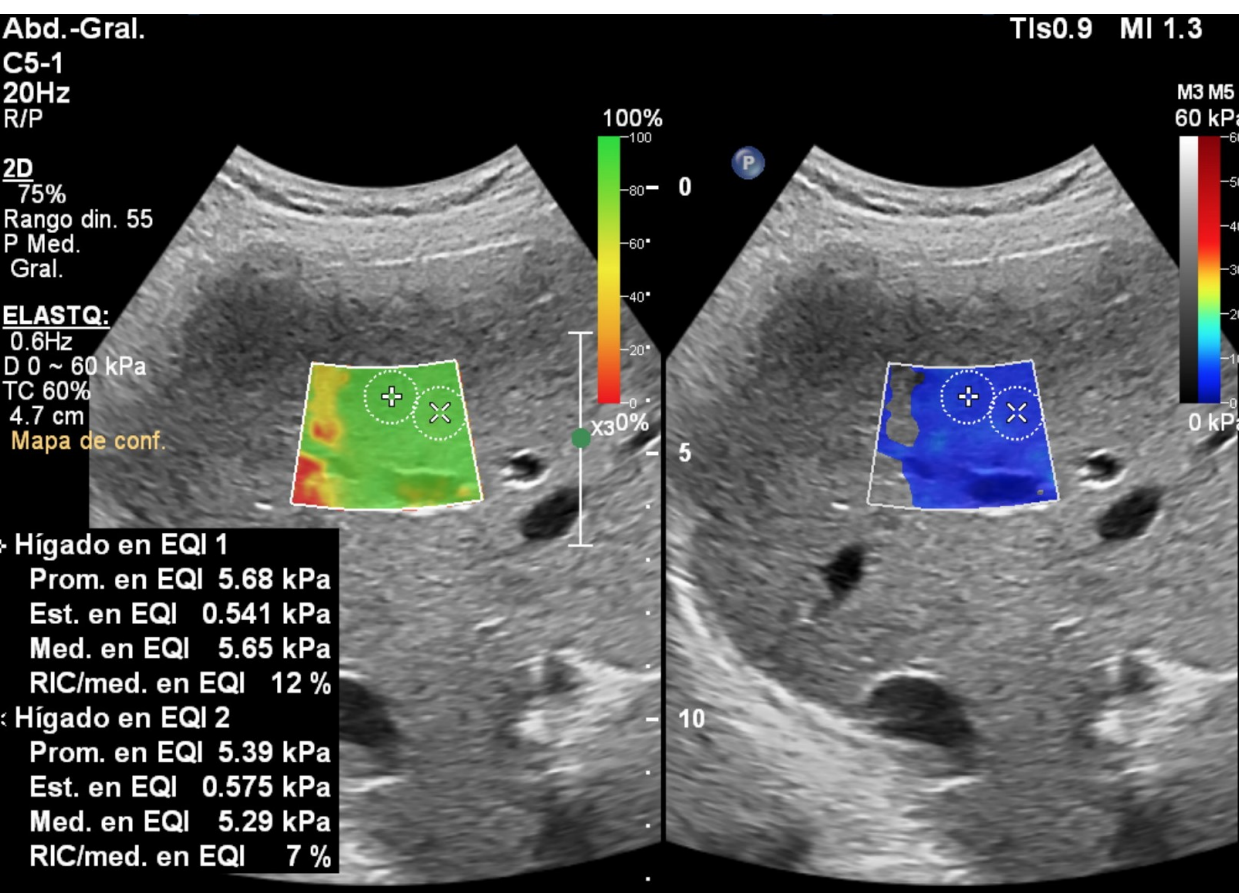


Strain elastography in Crohn's disease: the role of visual observation and semiquantitative parameters

Andrea Giannetti¹ · Marco Matergi¹ · Marco Biscontri¹ · Francesco Tedone¹ · Lucia Falconi¹ · Luca Giovannelli¹ · Valeria Ussia¹ · Luca Franci²




Ecografía intestinal: Otras Enteritis

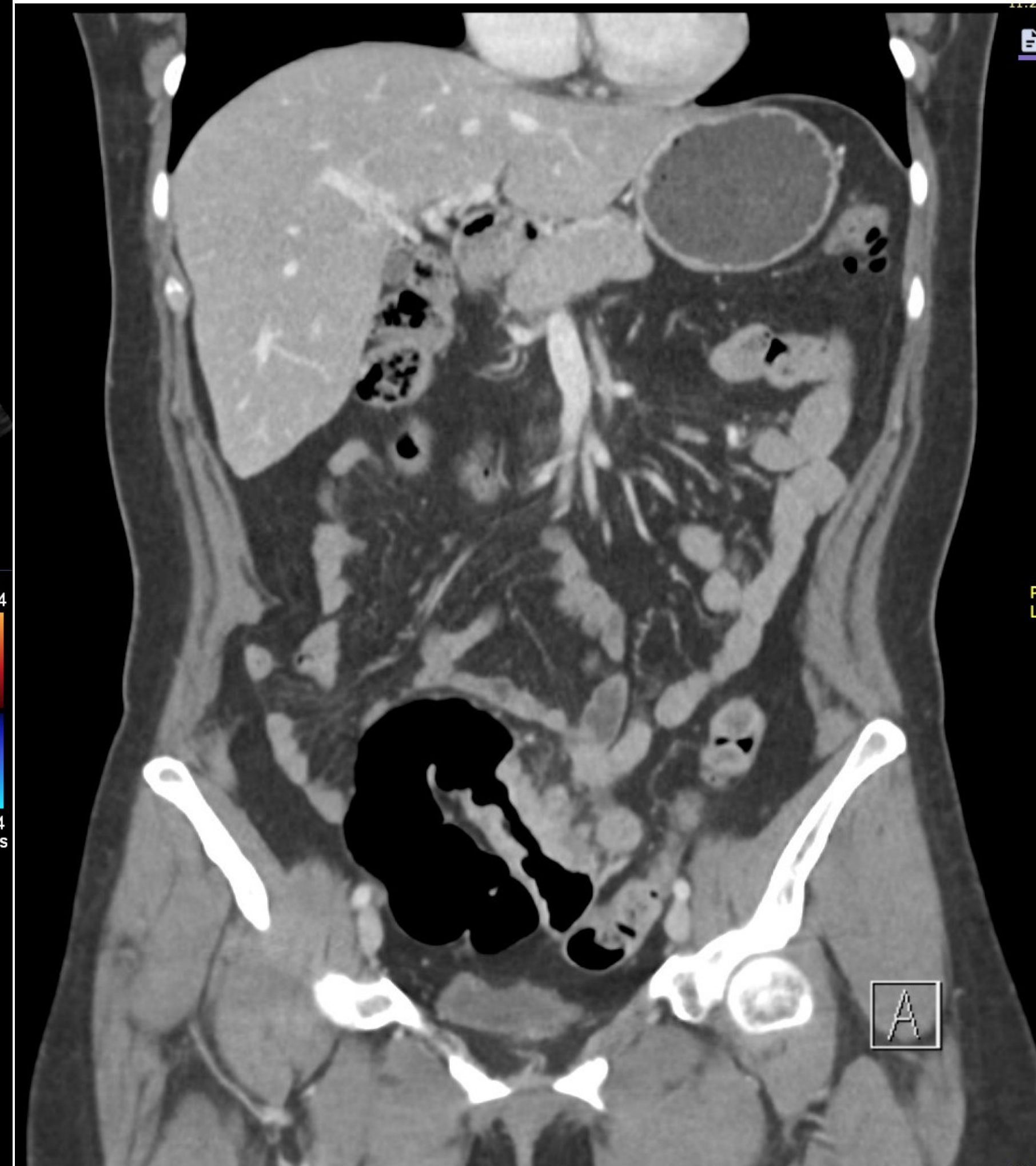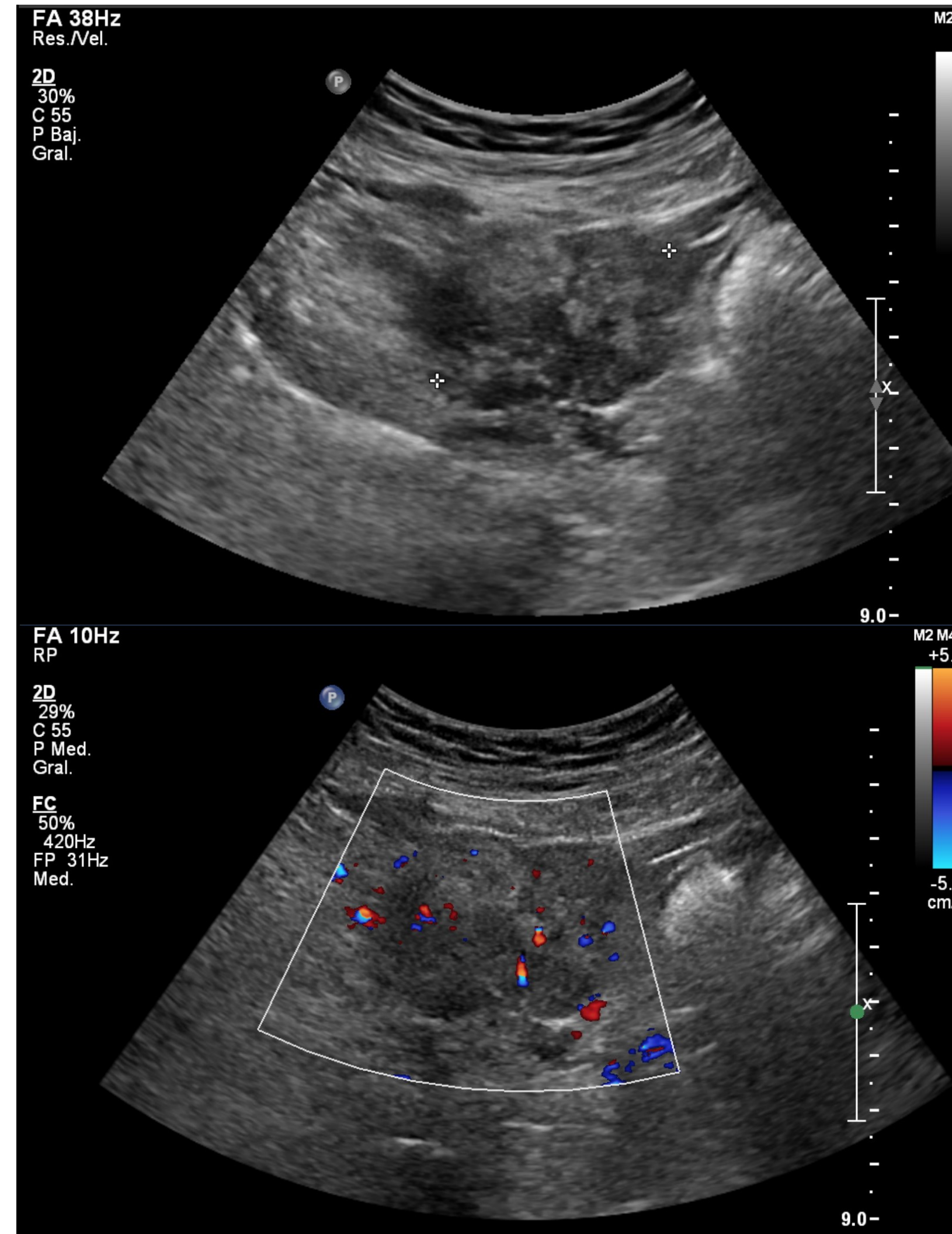
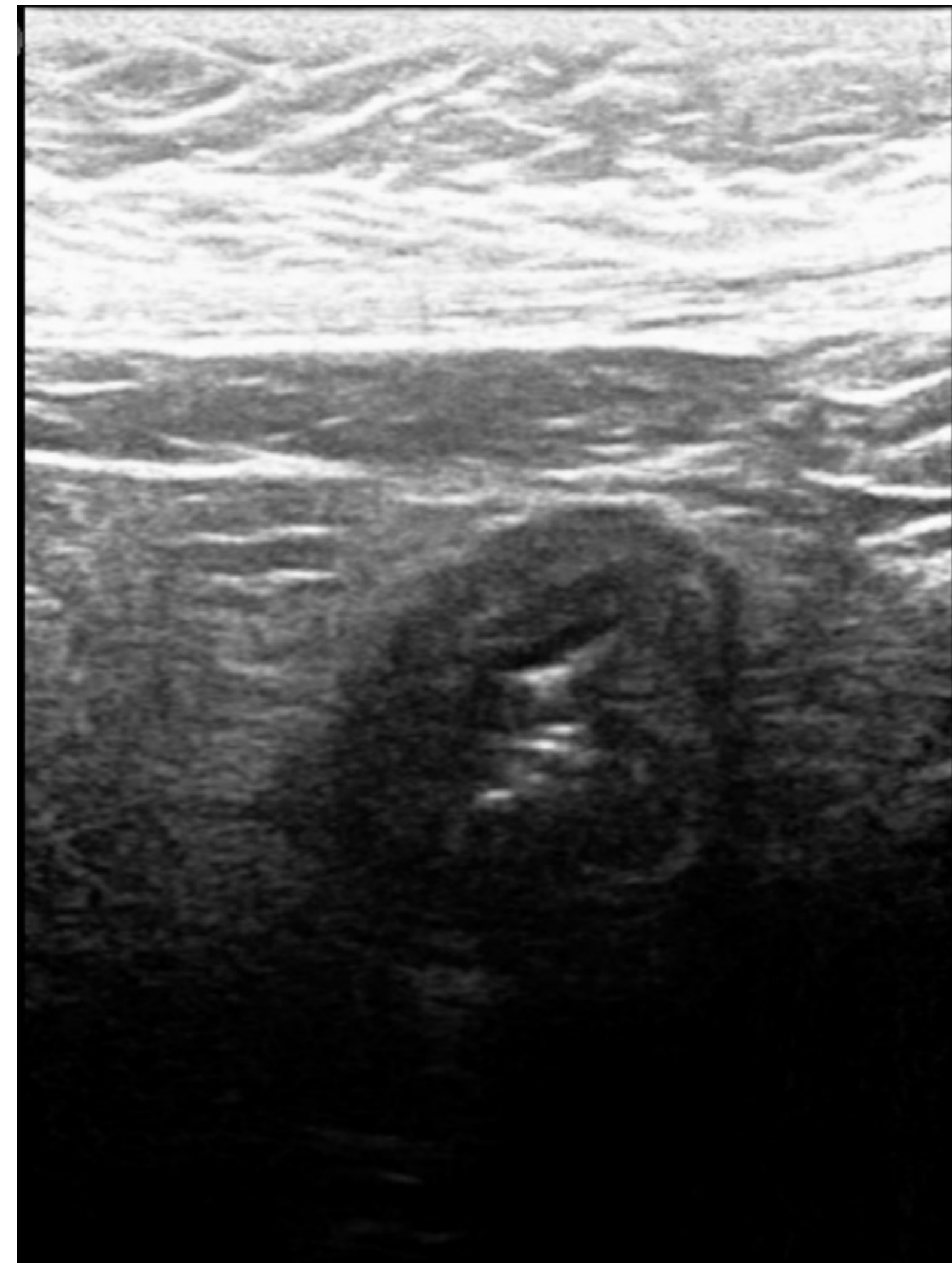


Leve esteatosis hepática asociado a elastografía hepática con valor de mediana de 5,65 kPa asociado a ausencia de signos ecográficos de daño hepático crónico, lo que descartaría Enfermedad hepática crónica avanzada compensada.
Hipoesplenía asociado a ileitis con engrosamiento y aumento de los pliegues. Se debe considerar Enfermedad celíaca

Ecografía intestinal: Neoplasia

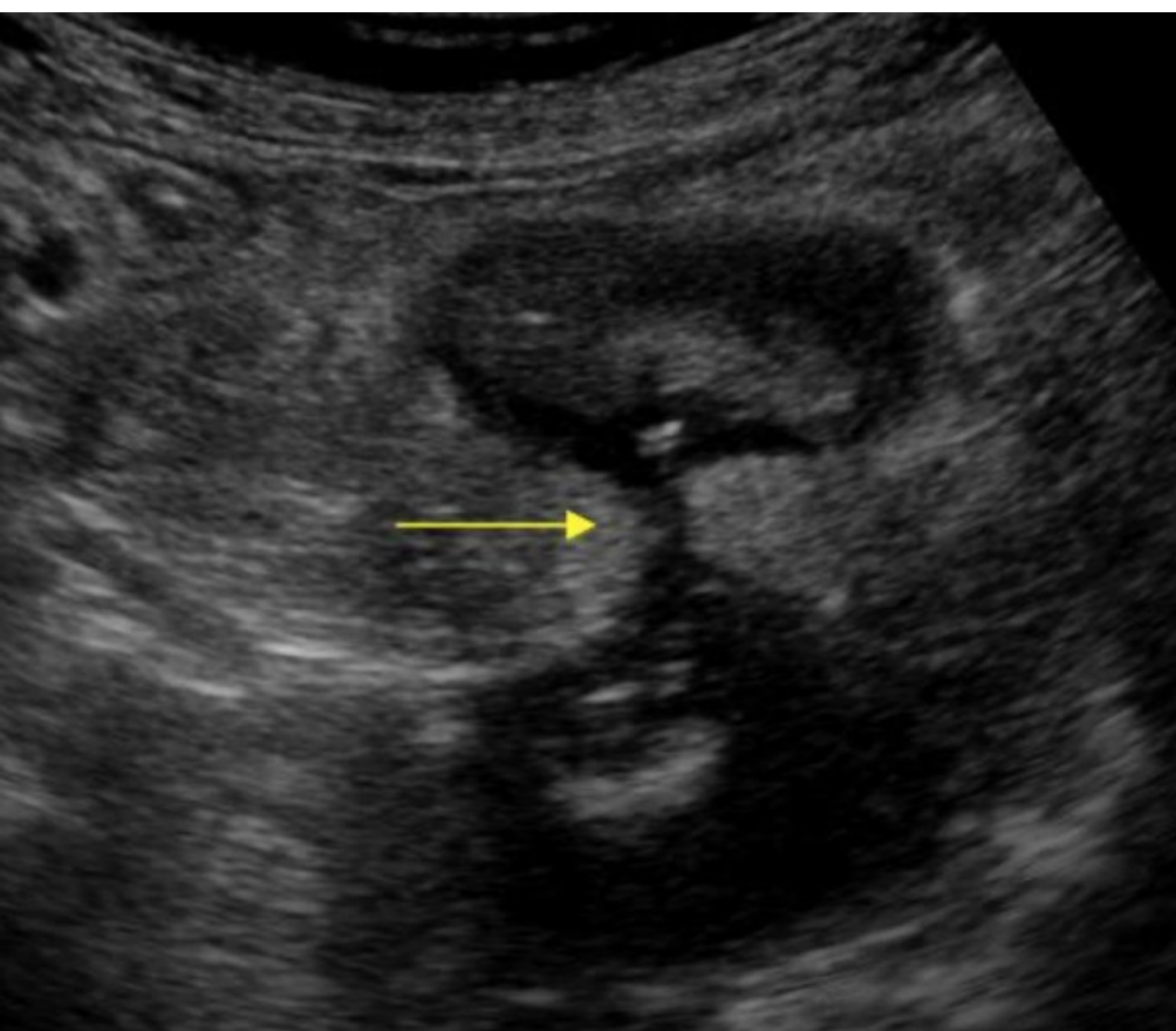


Dr. Juan
Salvador
Casas

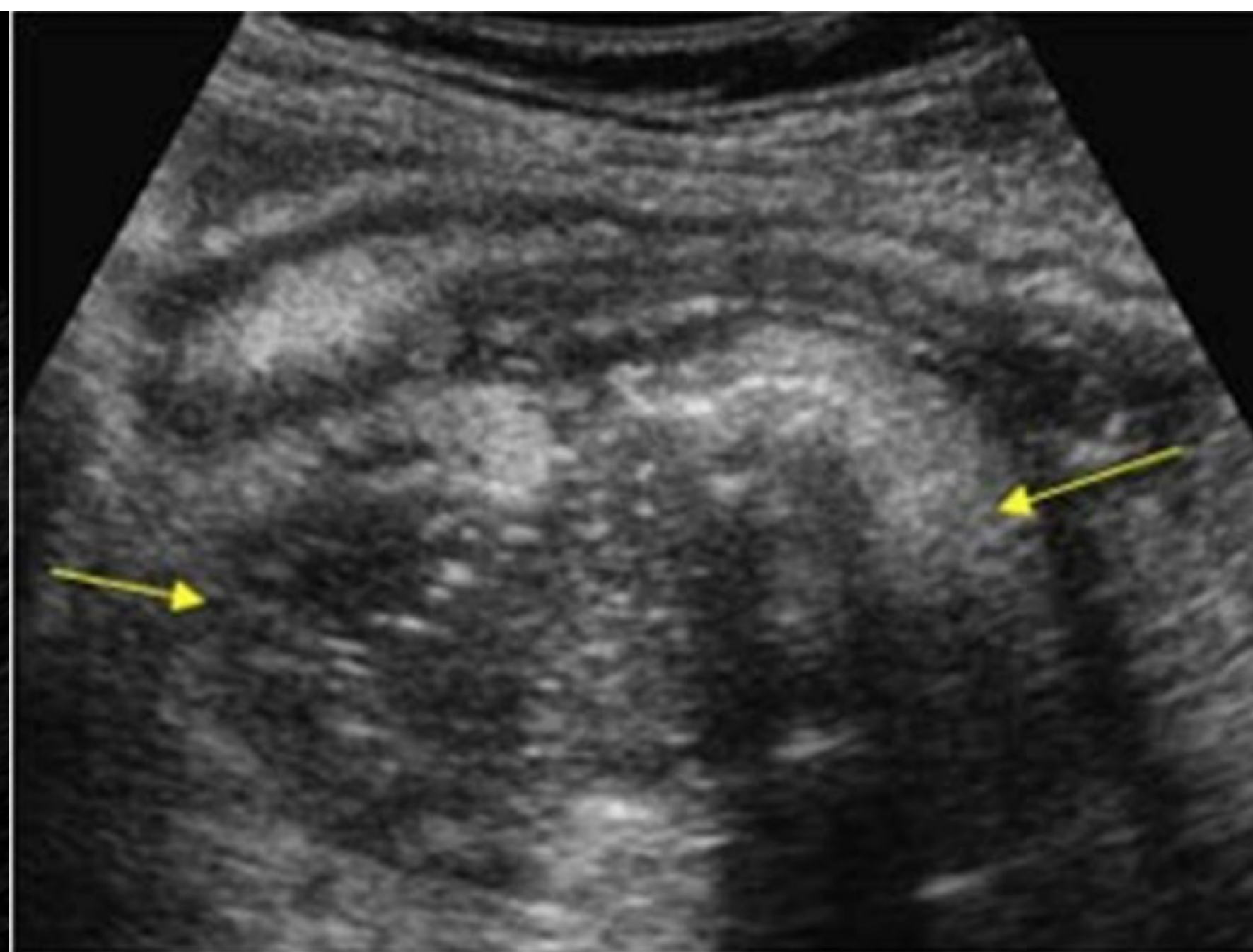


Conclusión

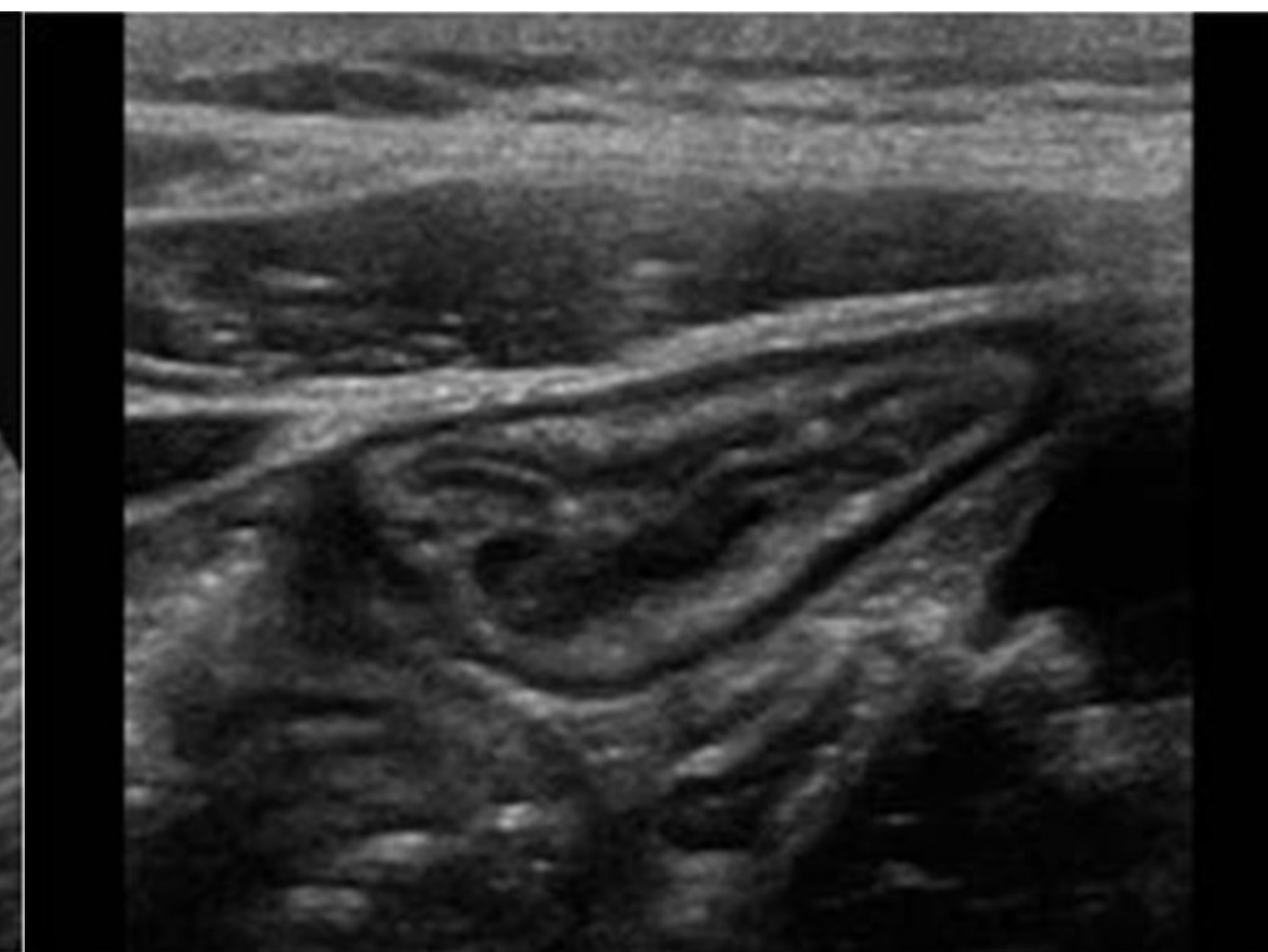
- La ecografía intestinal es una técnica que en manos expertas y dedicadas tiene indicaciones validas y con excelentes resultados diagnósticos y clínicos, tanto para patología aguda o crónica.



Fistulas



Abscesos



Ileitis

Reflexión final


"En cualquier tarea se puede ganar o perder, lo importante es la nobleza de los recursos utilizados"

La Ecografía es un técnica noble que hay que valorar, recuperar y fomentar para el beneficio de nuestros pacientes.



Marcelo Bielsa





Dr. Gonzalo Cárdenas Loguercio
gcardenas@hcuch.cl